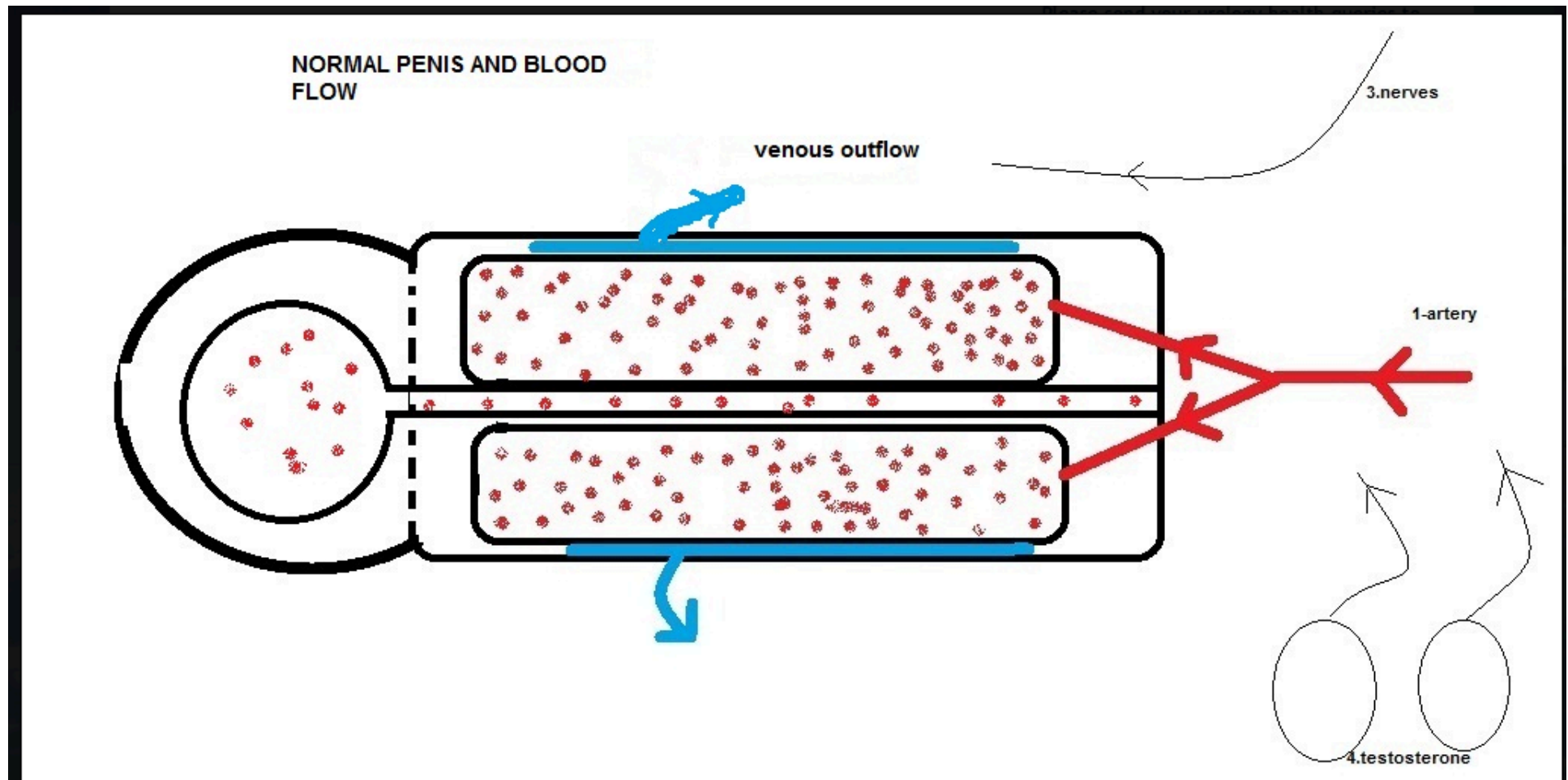


ΠΡΙΑΠΙΣΜΟΣ

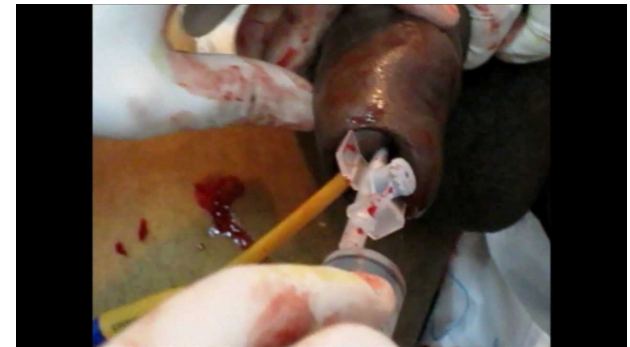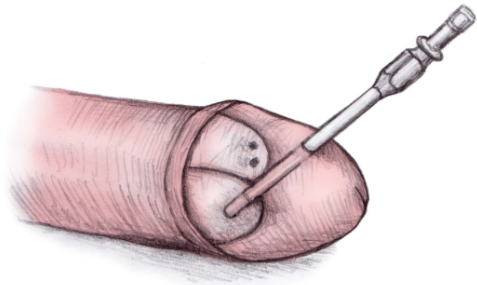
Στην ελληνική μυθολογία ο **Πρίαπος** ήταν θεός της γονιμότητας, προστάτης των αγροτικών ζώων, των φρουτοπαραγωγών φυτών, των κήπων και των ανδρικών γεννητικών οργάνων. Ο Ρωμαϊκός του αντίστοιχος ήταν ο ***Mutinus Mutunus***. Ήταν γιος του Διονύσου και της Αφροδίτης.



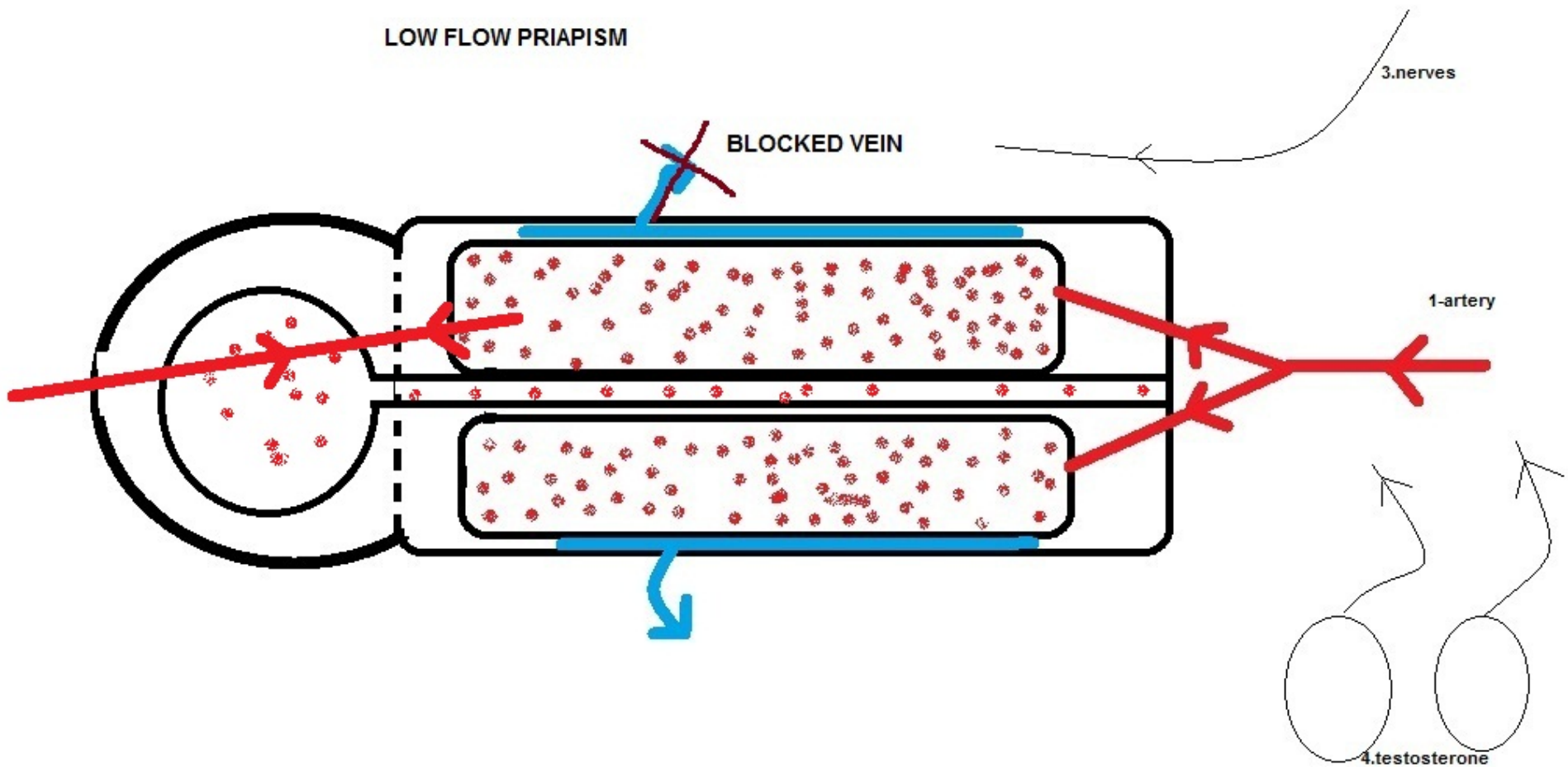
Φυσιολογική αιμάτωση



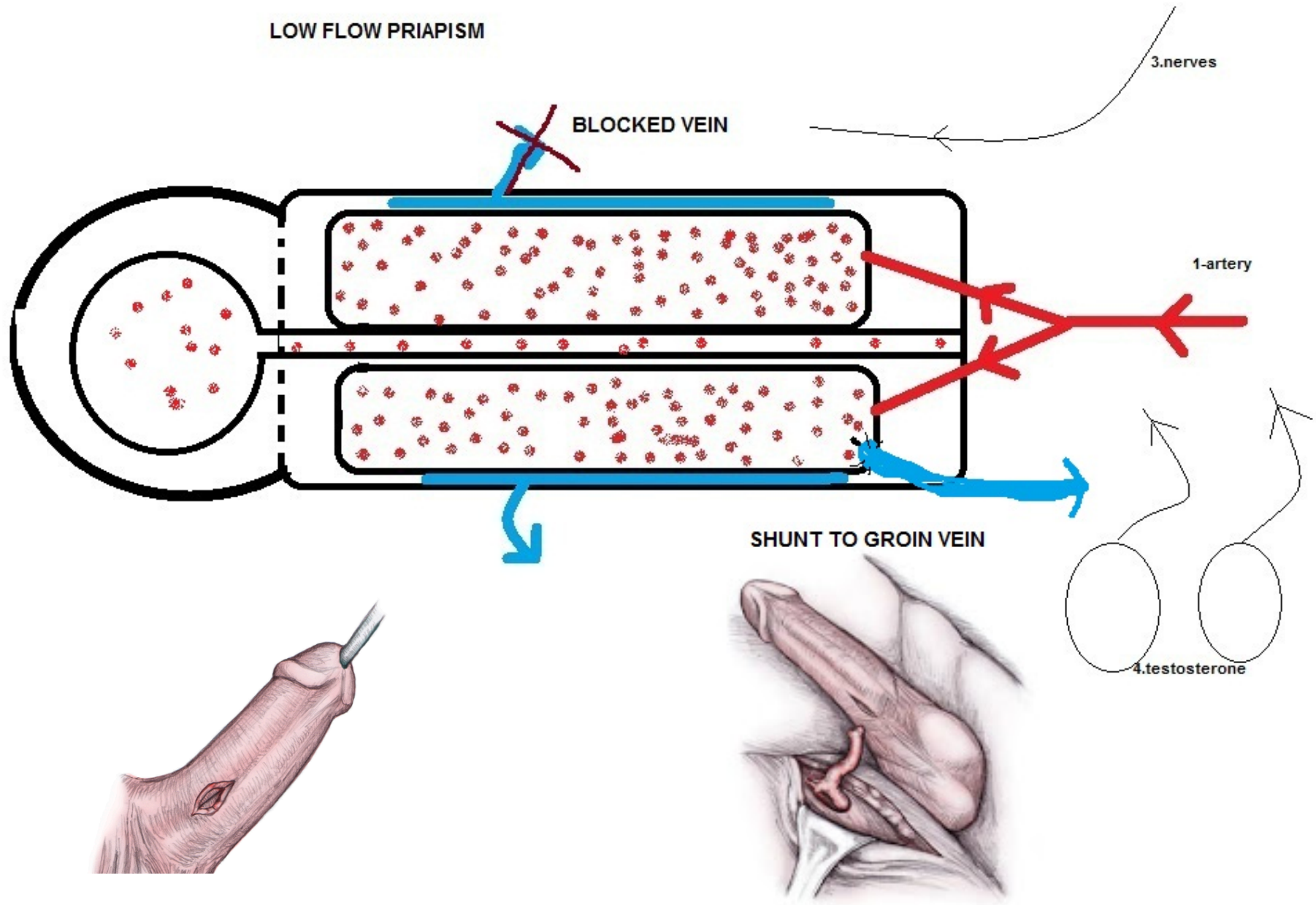
Πριαπισμός χαμηλής ροής - Ισχαιμικός



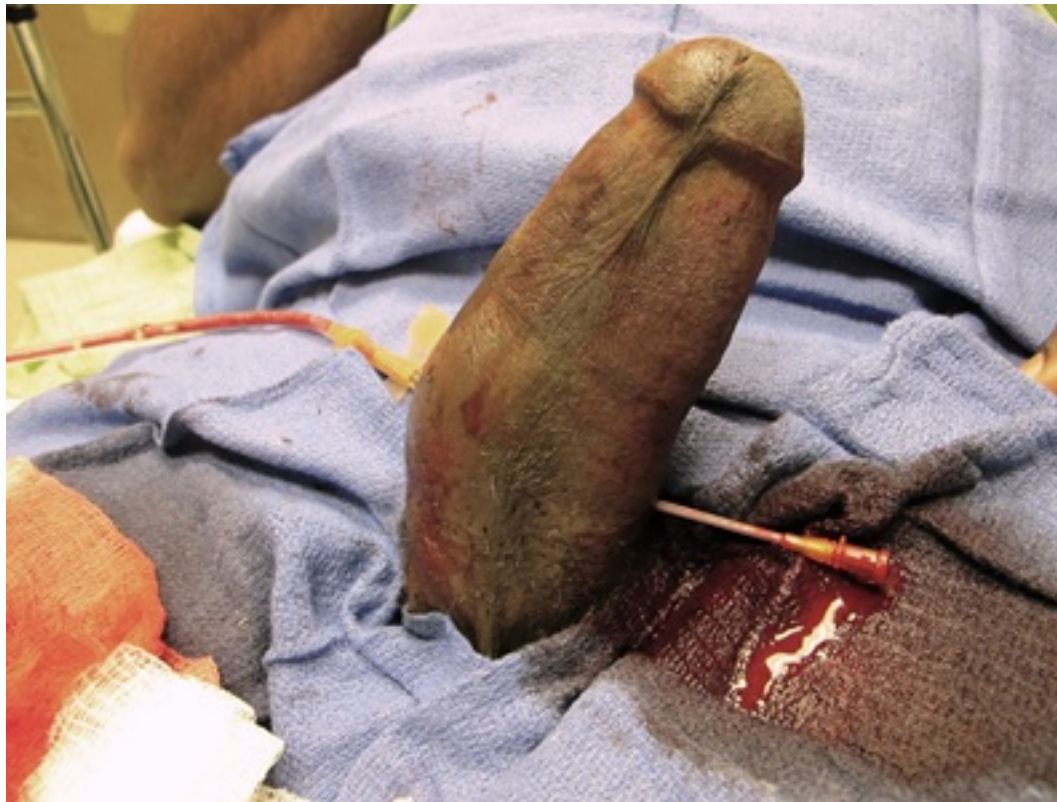LOW FLOW PRIAPISM



Πριαπισμός χαμηλής ροής - Ισχαιμικός



Η αφαίμαξη



Τι χρειαζομαι για την αντιμετώπιση;

PRIAPISM KIT



UroSciences

Innovations in Urology



SALINE FLUSH
10 mL (2)



Needles
16G x 1" (2)
27G x 1/2" (1)
27G x 1-1/4" (1)



BUTTERFLY 19G x 3/4" (1)



3-WAY PORT (1)



COHESIVE BANDAGE 1" (1)



SYRINGES
10 mL (1)
3 mL (1)
20 mL (1)



STERILE GLOVES (1)



BASIN (1)



POVIDONE-IODINE SWABSTICK (1)



STERILE DRAPE (1)



GAUZE
2"x 2" (2)
4"x 4" (4)
ALCOHOL PREP (4)

420 JERICHO TPK • SUITE 110 • JERICHO NY 11753 ~ 800-365-2839 ~ www.UroSciences.com

LOT:

FOR PROFESSIONAL USE ONLY

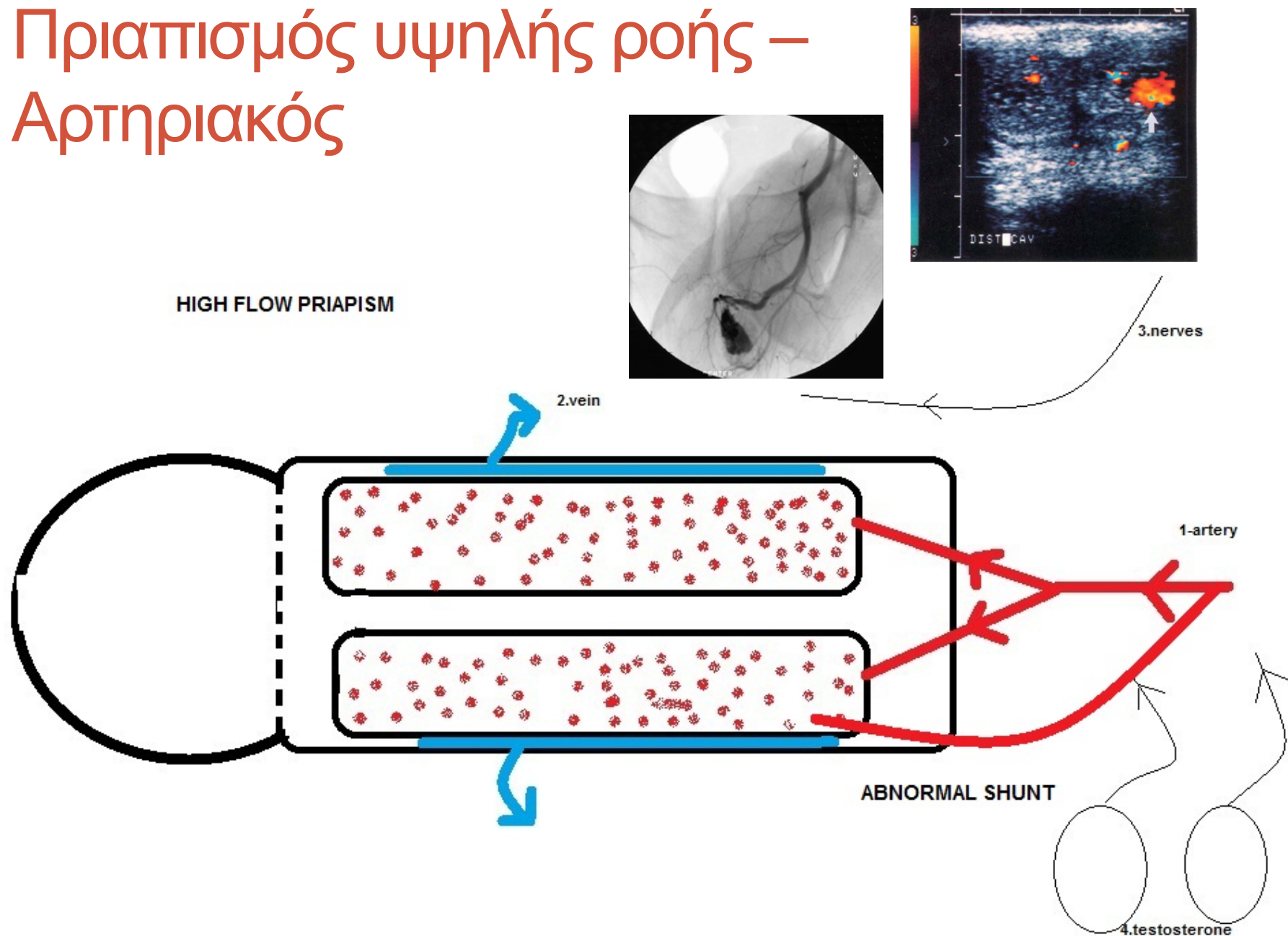
EXP:

ΑΝΤΙΜΕΤΩΠΙΣΗ

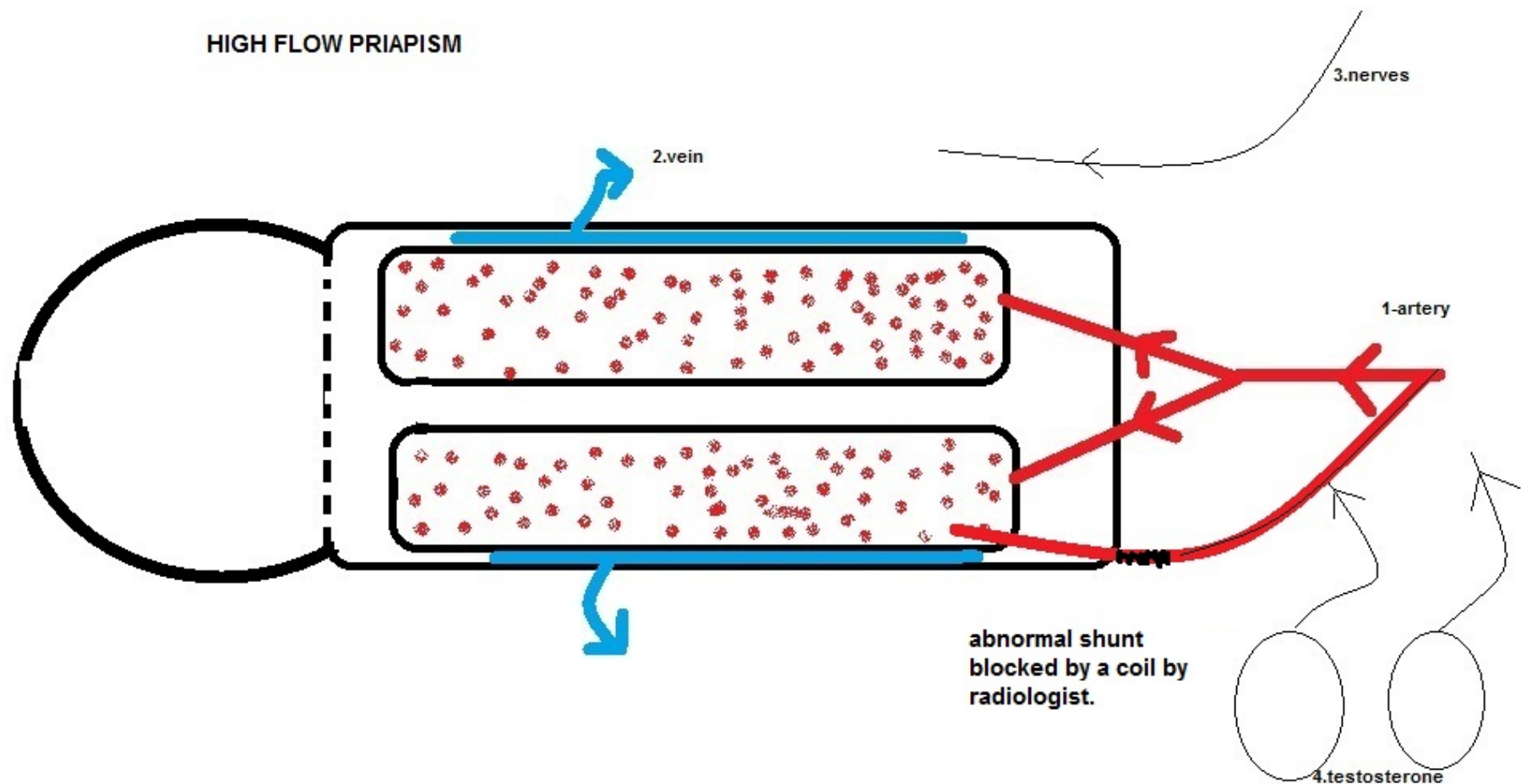
Time Interval (Hr)	Treatment
0-<2	Home: encourage patient to urinate, increase fluid intake, exercise, and take oral analgesics
2-<4	Emergency department: i.v. hydration and i.v. analgesics; may also give anxiolytics (e.g., lorazepam, midazolam, or hydroxyzine) or oxygen if needed
4-<12	Intracavernosal aspiration of blood and instillation of an α -agonist (phenylephrine or epinephrine) with local anesthesia; repeat as needed. Continue i.v. hydration, analgesics, anxiolytics, and oxygen
≥ 12 (sooner if medically indicated)	Surgical consult for shunt placement

Source: Am J Health-Syst Pharm © 2004 American Society of Health-System Pharmacists

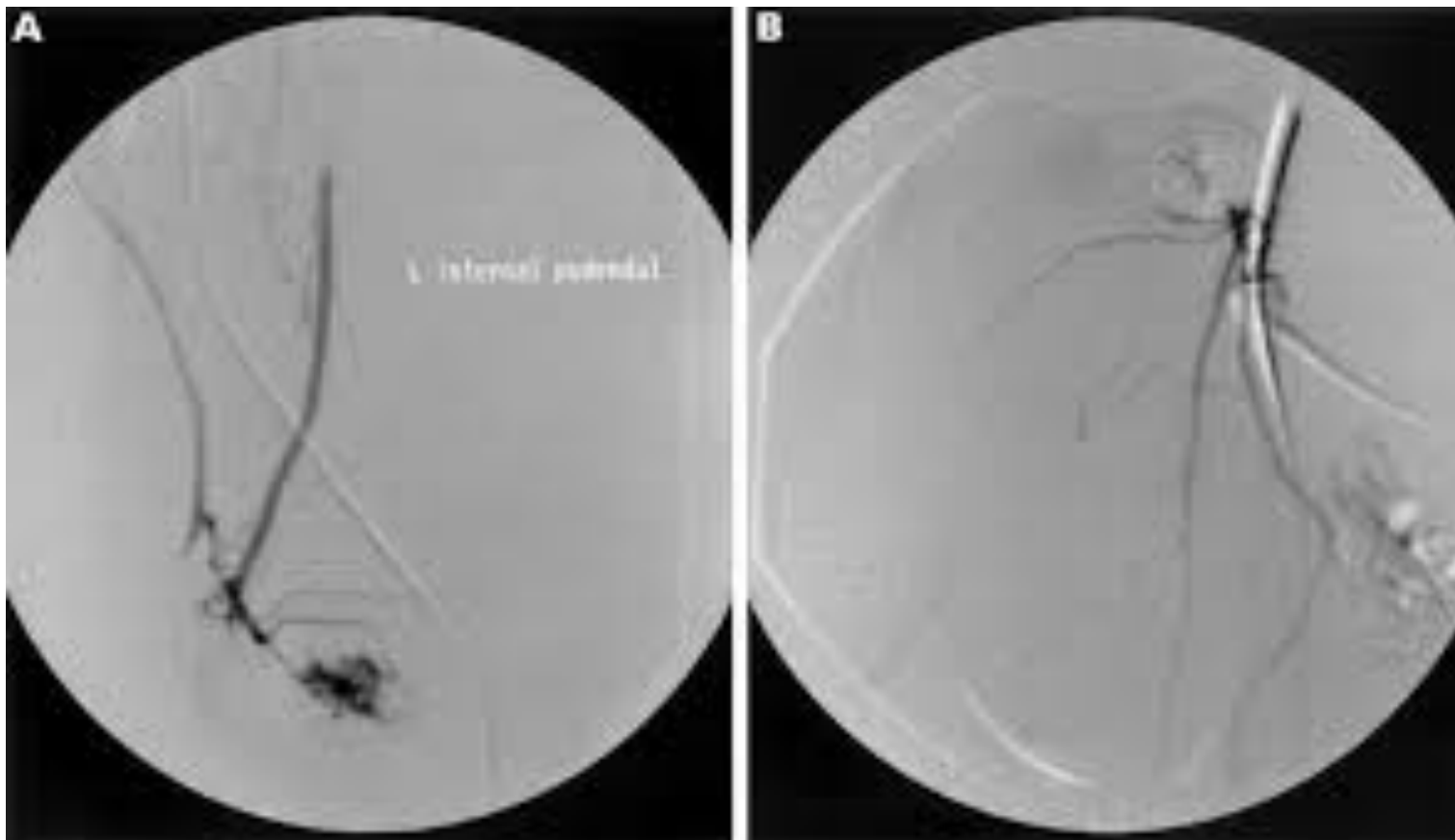
Πριαπισμός υψηλής ροής – Αρτηριακός



Πριαπισμός υψηλής ροής – Αρτηριακός



Ο εμβολισμός



Αρτηριακός πριαπισμός

[J Urol. 2002 Nov;168\(5\):2074-7.](#)

Management strategy for arterial priapism: therapeutic dilemmas.

[Hatzichristou D¹](#), [Salpiggidis G](#), [Hatzimouratidis K](#), [Apostolidis A](#), [Tzortzis V](#), [Bekos A](#), [Saripoulos D](#).

⊕ Author information

Abstract

PURPOSE: We present 7 cases of arterial high flow priapism and propose management algorithms for the condition.

MATERIALS AND METHODS: We studied 2 children and 5 adults with posttraumatic arterial priapism. Blood gas analysis and color Doppler ultrasonography of the corpora cavernosa confirmed the diagnosis in 4 adults, while 1 patient had already undergone cavernous artery ligation in elsewhere. In the children perineal compression resulted in detumescence, a sign that is proposed to be indicative of the diagnosis of arterial priapism (piesis sign) complementing physical examination. Mechanical compressive force was applied to the perineum of 1 boy, while the other received a watchful waiting program. All adults participated in an observation regimen except 1, who decided to undergo immediate embolization of the internal pudendal artery.

RESULTS: Perineal compression led to the resolution of priapism in 1 child, while spontaneous resolution was noted in the other. An adult noticed spontaneous penile detumescence 3 to 4 months after trauma, which was attributable to site specific venous leakage and decreased, inflow in the contralateral cavernous artery. The patient underwent venous surgery and is on an intracavernous injection regimen. Successful embolization of the internal pudendal artery was performed immediately in 1 man and in the other 4 months after trauma due to social inconvenience. Adult patient 3 is still on the watchful waiting protocol (42 months), while the one who underwent cavernous artery ligation is receiving treatment for erectile dysfunction.

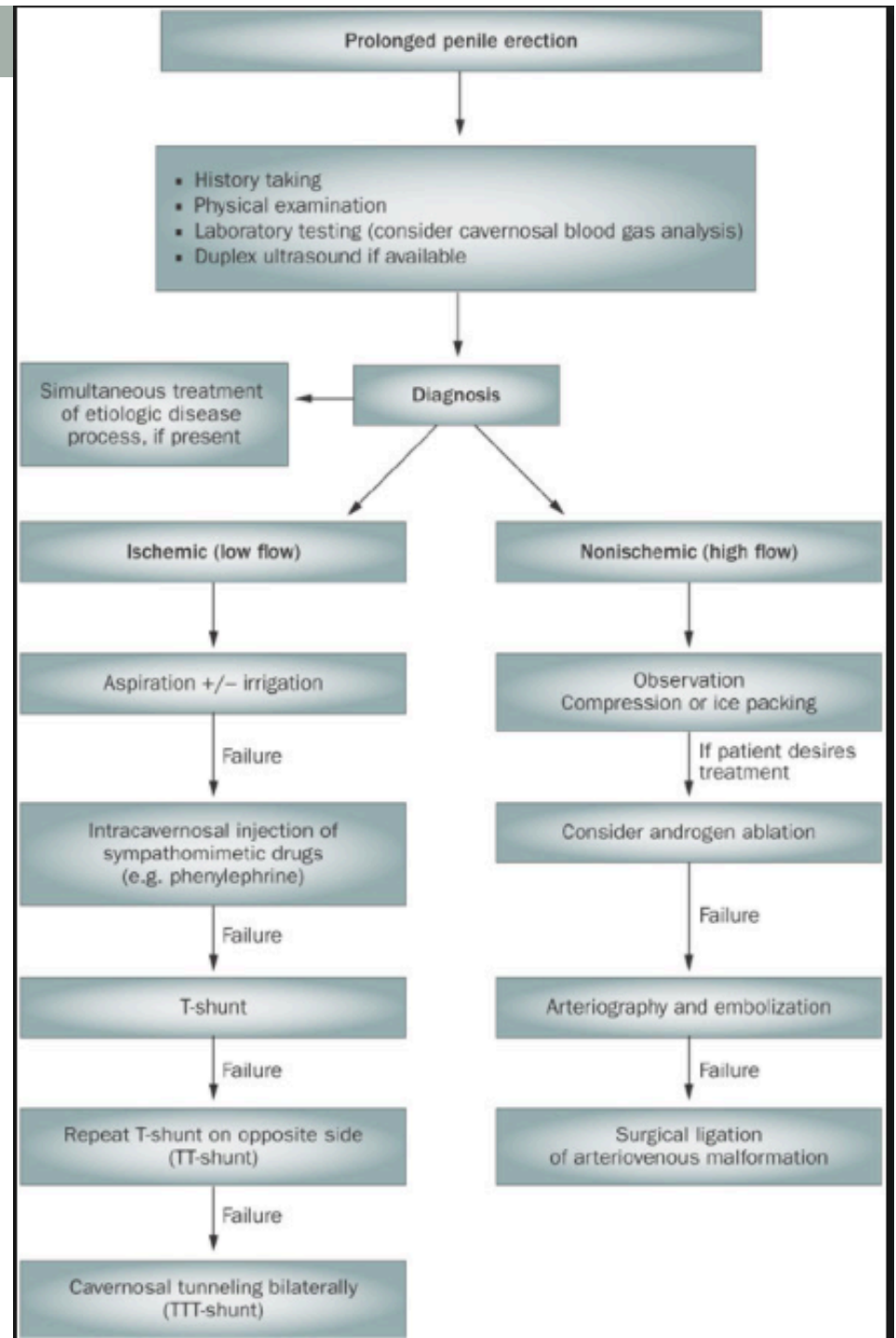
CONCLUSIONS: Absent of long-term damaging effects of arterial priapism on erectile tissue combined with the possibility of spontaneous resolution or progressive concomitant hemodynamic abnormalities associated with blunt perineal trauma are suggestive of the introduction of an observation period in the management algorithm of high flow priapism. Such a period may help avoid unnecessary intervention and determine the impact of priapism on patient personal life. Perineal compression may be also added as part of the physical examination as a sign specifically indicative of arterial priapism.

Συμπτώματα

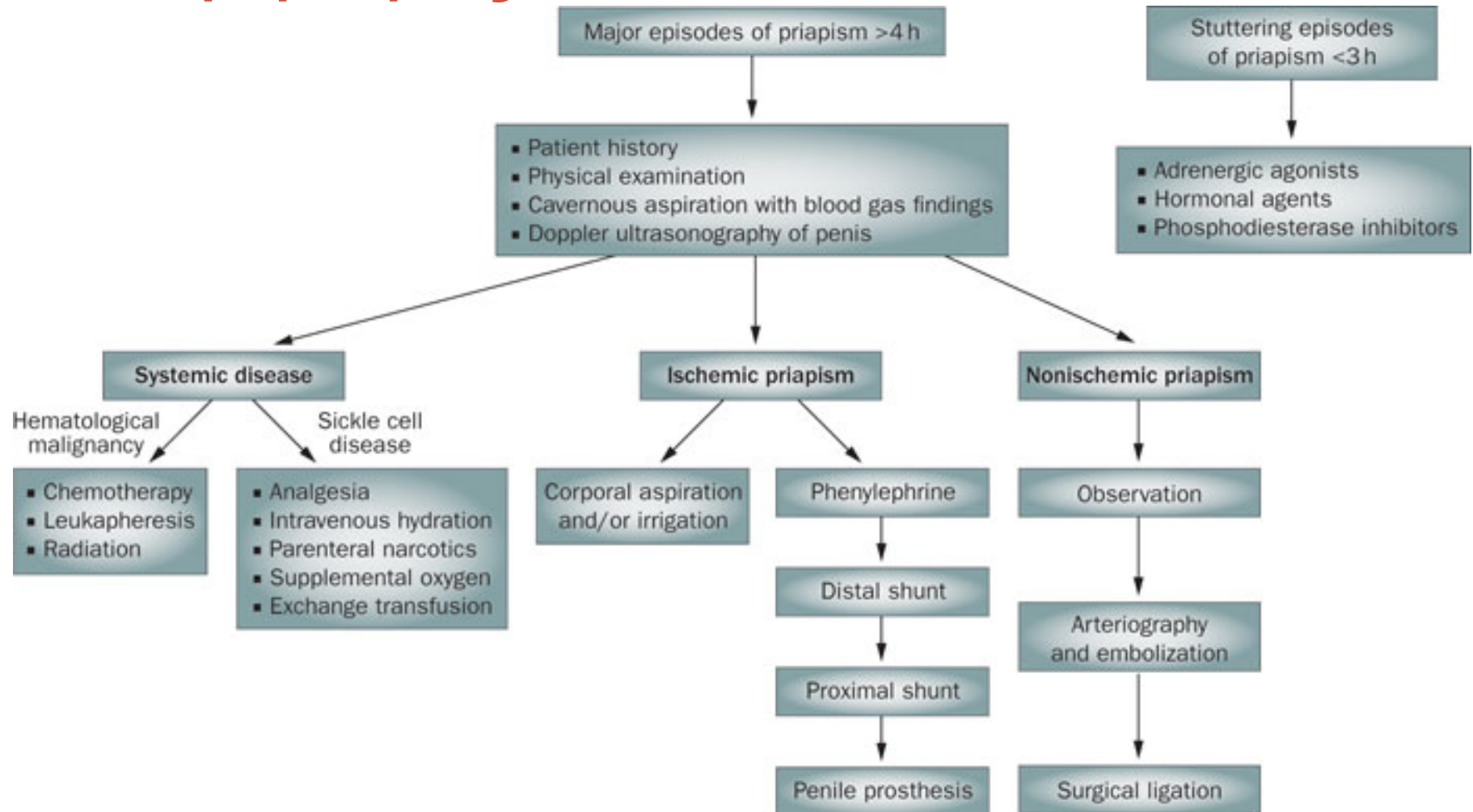
Evaluation of Priapism¹

Key Finding	Ischemic	Nonischemic
Corpora cavernosa fully rigid	Usually present	Seldom present
Penile pain	Usually present	Seldom present
Blood abnormalities or hematological malignancy	Sometimes present	Seldom present
Chronic tumescence without full rigidity	Seldom present	Usually present
Perineal trauma	Seldom present	Sometimes present

ΑΝΤΙΜΕΤΩΠΙΣΗ



Ο αλγόριθμος

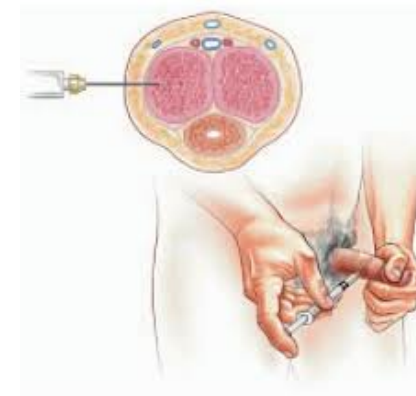


Οι χειρουργικές επεμβάσεις

Surgical techniques for different types of shunt [1,4,10,11,22-30]

Shunts	Procedure
Winter	Direct insertion of 'Tru-cut' biopsy needle through the glans into the corpora cavernosa.
Ebbehoj	Direct insertion of no. 11 scalpel through the glans into the corpora cavernosa.
T-shunt	At least 4 mm away from external urethral meatus, no. 10 scalpel is inserted through the glans into one of the corpora cavernosa, rotated 90° away from the urethra, and then removed.
TT-shunt	For priapism lasting >72 hours, by creating bilateral cavernoglanular fistulae. Bilateral intracavernosal tunnel can be created by a 20-Fr dilator, to maximize shunting of blood proximal to distally.
Al-Ghorab	A 2-cm incision is made transversely just distal to the coronal sulcus. A corporoglandular shunt is created by excision of tunica albuginea layer of both corpora cavernosa.
Corporal 'snake'	Modification of Al-Ghorab shunt, size 7/8 Hegar dilator is advanced several centimeters into bilateral corpora cavernosa. Blood is evacuated by milking the penis proximal to distally.
Quackels	Unilateral cavernospongiosal shunt is formed by anastomosing proximal corpora cavernosa to corpus spongiosum. A wedge tissue of corporocavernosal and spongiosal tissue is excised and sutured together.
Sacher	Similar to Quackels, cavernospongiosal shunt is performed bilaterally.
Grayhack	Caverno-saphenous shunt is created between the corpus cavernosum and saphenous vein. A length of 8-10 cm of saphenous vein distal to the fossa ovalis is mobilized and anastomosed end to side in the corpus cavernosum.
Barry	Caverno-dorsal vein shunt is achieved by identifying and mobilizing the dorsal vein of the penis, ligating and dividing the distal part, and anastomosing the proximal part to the corpus cavernosum without any tension.

Η πρώτη δημοσίευση



J Urol. 1991 Apr;145(4):764-7.

Recurrent prolonged erections and priapism as a sequela of priapism: pathophysiology and management.

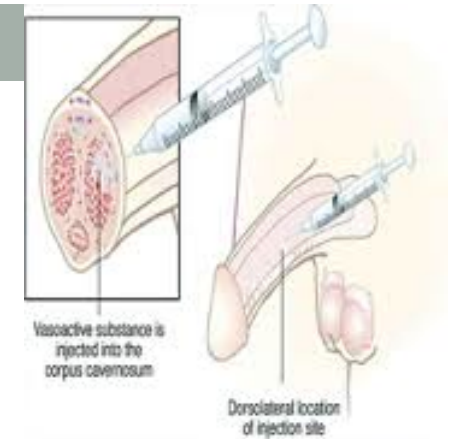
Levine JF¹, Saenz de Tejada I, Payton TR, Goldstein I.

⊕ Author information

Abstract

Veno-occlusive priapism may be associated with prolonged corporeal ischemia, subsequent fibrosis of the corpora and impotence. We report on 6 patients who presented with an unusual sequela of veno-occlusive priapism, recurrent episodes of prolonged erections or priapism. In all cases the subsequent episodes were idiopathic and veno-occlusive, occurred with a frequency ranging from several times per day to once per month and were symptomatically disabling. Pharmacocavernosometry ruled out mechanical occlusion of corporeal venous drainage by demonstrating elevated flows to maintain intracavernosal pressures following smooth muscle contraction and markedly decreased flow rates following smooth muscle relaxation. Treatment of the recurrent episodes with intracavernous self-injection of phenylephrine resulted in successful detumescence. The use of oral phenylpropanolamine reduced the frequency and duration of the recurrences, and markedly reduced the need for adrenergic self-injection. It is proposed that this syndrome may develop secondary to the initial ischemic episode, resulting in a functional alteration of the adrenergic and/or endothelial-mediated mechanisms that control penile tumescence and maintain penile flaccidity.

Η φαινυλεφρίνη



J Sex Med. 2006 Sep;3(5):918-22.

Management of ischemic priapism with high-dose intracavernosal phenylephrine: from bench to bedside.

Munarriz R¹, Wen CC, McAuley I, Goldstein I, Traish A, Kim N.

⊕ Author information

Erratum in

J Sex Med. 2006 Sep;3(5):938.

Abstract

INTRODUCTION: Ischemic priapism is associated with cavernosal acidosis, which decreases the efficacy of adrenergic agonists. We determined the effect of acidosis on ligand dissociation from adrenergic receptors and assessed the efficacy of high-dose phenylephrine in treating patients with acute ischemic priapism.

METHODS: Dissociation rates of [3H]prazosin were determined at pH 7.2 and 6.9 in membrane preparations of rabbit penile cavernosal tissue. Vital signs were recorded from patients before injection, and at 1 minute and 5 minutes after injection of high-dose phenylephrine (1,000 mg q 5 minutes) for 17 consecutive cases of iatrogenic ischemic priapism that occurred after vascular assessment. We also provide two case reports of prolonged ischemic priapism successfully managed with high-dose phenylephrine.

RESULTS: Dissociation rates of [3H]prazosin were greater at pH 6.9 ($K(-1) = 0.23/\text{minute}$) than at pH 7.2 ($K(-1) = 0.10/\text{minute}$), suggesting decreased receptor affinity at acidic pH. Intracavernosal therapy with high-dose phenylephrine (mean dose 2,059 \pm 807 microg) was 100% effective with no adverse events or significant changes in vital signs. In addition, two patients with ischemic priapism for $>$ or $=$ 36 hours were successfully treated with high-dose intracavernosal phenylephrine (mean dose 45,000 microg) without any adverse event. Both patients are currently potent.

CONCLUSIONS: Acidic pH may decrease the binding affinity of adrenergic ligands to their receptors. Phenylephrine at doses higher than previously reported may be necessary to overcome this decreased affinity in acidosis associated with ischemic priapism. High-dose intracavernosal phenylephrine administration is safe and effective in the management of ischemic priapism. Continuous cardiovascular monitoring is advised.

Η διγοξίνη

[J Urol.](#) 1998 May;159(5):1529-36.

A possible mechanism for alteration of human erectile function by digoxin: inhibition of corpus cavernosum sodium/potassium adenosine triphosphatase activity.

[Gupta S¹](#), [Salimpour P](#), [Saenz de Tejada I](#), [Daley J](#), [Gholami S](#), [Daller M](#), [Krane RJ](#), [Traish AM](#), [Goldstein I](#).

+ Author information

Abstract

PURPOSE: Digoxin use has long been recognized to affect adversely male sexual function but the underlying mechanism is poorly understood. Digoxin is a known inhibitor of sodium/potassium adenosine triphosphatase (sodium pump), a plasma membrane enzyme that has a role in the regulation of smooth muscle tone. We investigated the effects of digoxin on human corpus cavernosum smooth muscle contractility and overall erectile function.

MATERIALS AND METHODS: In human corporeal smooth muscle strips the in vitro effects of digoxin were assessed on sodium pump activity as measured by digoxin inhibitable uptake of ⁸⁶rubidium, basal tone and endothelium dependent, neurogenic and nitric oxide donor induced relaxation. An in vivo prospective double-blind, placebo controlled, crossover, 4-period investigation was performed in 6 healthy male volunteers. The effects of digoxin on serum hormones, erectile function questionnaire, visual sexual stimulation and nocturnal penile tumescence were recorded.

RESULTS: In vitro digoxin caused concentration dependent inhibition of ⁸⁶rubidium uptake (half maximum effect at 0.01 microM.) and contraction of corporeal smooth muscle (half maximum effect at 0.8 microM.). Therapeutic concentrations of digoxin (2 nM.) also inhibited relaxation induced by acetylcholine and electrical field stimulation, which release nitric oxide from corpus cavernosum endothelial cells and nonadrenergic noncholinergic nerves, respectively. In vivo digoxin diminished penile rigidity during visual sexual stimulation and nocturnal penile tumescence testing compared to placebo without influencing libido or serum testosterone, estrogen or luteinizing hormone levels.

CONCLUSIONS: Digoxin associated alteration of human erectile function may be explained, in part, by inhibition of corporeal smooth muscle sodium pump activity, which promotes contraction and impedes nitric oxide induced relaxation. Such findings suggest therapeutic use of digoxin for treatment of recurrent priapism states.

O_i PDE5_i

Urology. 2006 May;67(5):1043-8.

Long-term oral phosphodiesterase 5 inhibitor therapy alleviates recurrent priapism.

Burnett AL¹, Bivalacqua TJ, Champion HC, Musicki B.

⊕ Author information

Abstract

OBJECTIVES: Recurrent ischemic priapism describes a disorder of repeated episodes of prolonged penile erection that frequently leads to devastating complications of erectile tissue damage and erectile dysfunction. A mechanistic role for dysregulated phosphodiesterase 5 (PDE5) in the deranged smooth muscle response of the corpus cavernosum of the penis offers new understanding about the pathogenesis of the disorder and suggests that PDE5 may serve as a molecular target for its treatment and prevention. We explored the use of PDE5 inhibitors to treat recurrent priapism, based on the hypothesis that the erection regulatory function of PDE5 would be regularized by this treatment and protect against further episodes.

METHODS: We administered PDE5 inhibitors using a long-term therapeutic regimen to 3 men with sickle cell disease-associated priapism recurrences and 1 man with idiopathic priapism recurrences.

RESULTS: Long-term PDE5 inhibitor treatment alleviated priapism recurrences.

CONCLUSIONS: These observations support the hypothesis that PDE5 dysregulation exerts a pathogenic role for priapism associated with hematologic dyscrasias, as well as idiopathic priapism. Although these preliminary findings suggest that continuous, long-term PDE5 inhibitor therapy may be useful as a preventative strategy for priapism, additional evaluation in the form of a controlled clinical trial is needed.

Οι ανεπιθύμητες των φαρμάκων

Pharmacologic management of ischemic priapism [5,7]

Treatment (class, drug, and dosage)	Side effect and precaution
Adrenergic system effectors (intracavernosal)	
Phenylephrine 100-500 mcg prn; 20 mL of 10 mcg/mL solution every 2 minutes (maximum 200 mL or 15-20 mL of 20 mcg/mL solution)	Hypertension, palpitations
Etilefrine, 5-10 mg prn	Hypertension, palpitations
Ephedrine, 50-100 mg prn	Tachycardia, angina
Epinephrine 10-20 mcg prn; 20 mL of 1 mcg/mL solution every 2 minutes	Hypertension, palpitations, tachycardia
Norepinephrine, 10-20 mcg prn	Hypertension, palpitations, tachycardia
Metaraminol, 2-4 mg prn	Hypertension, palpitations, tachycardia
Guanylatecyclase inhibitors (intracavernosal)	
Methylene blue, 50-100 mg prn	Penile burning

Η ώρα της πρόθεσης

