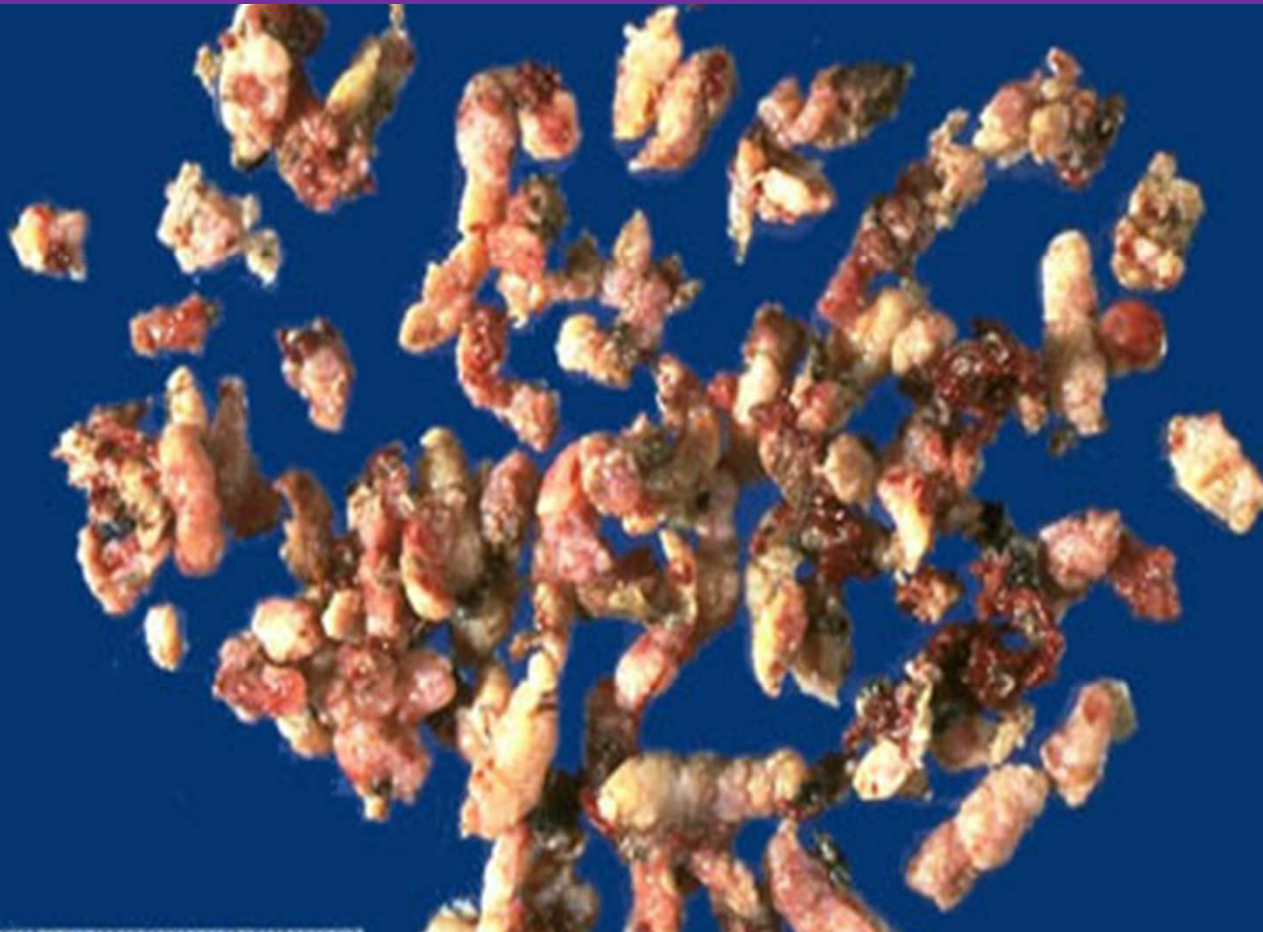


ΔΙΟΥΡΗΘΡΙΚΗ ΠΡΟΣΤΑΤΕΚΤΟΜΗ

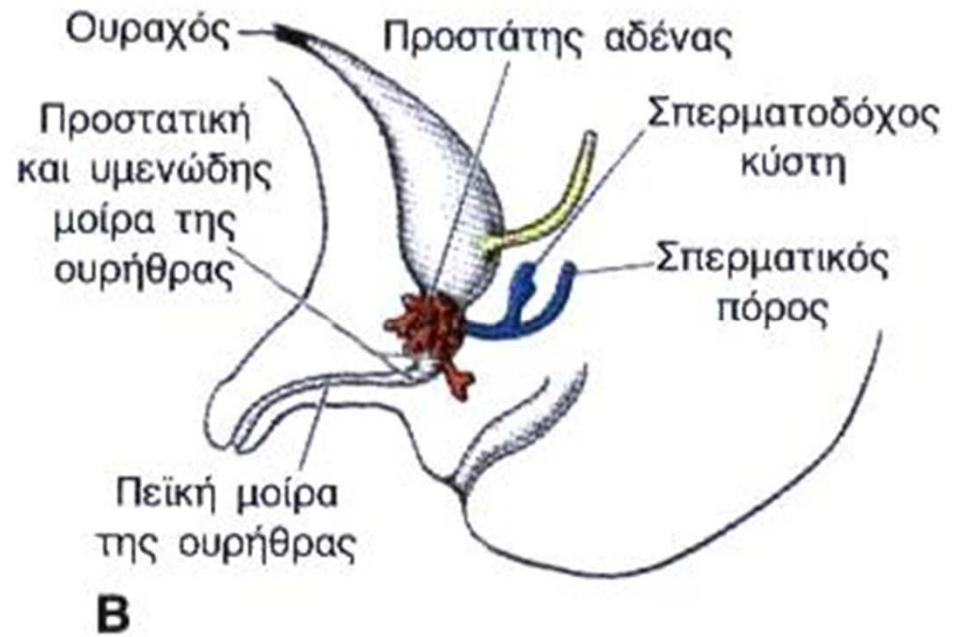
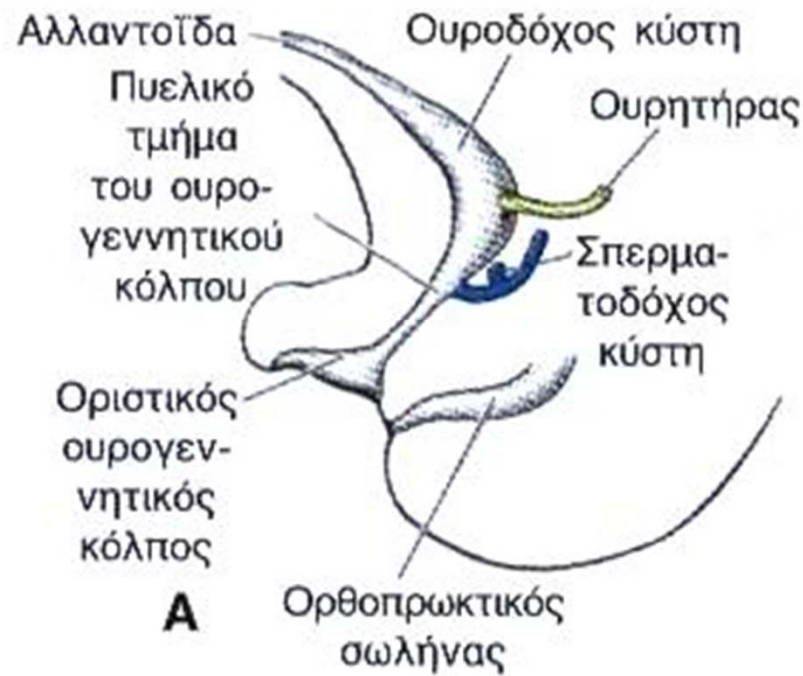

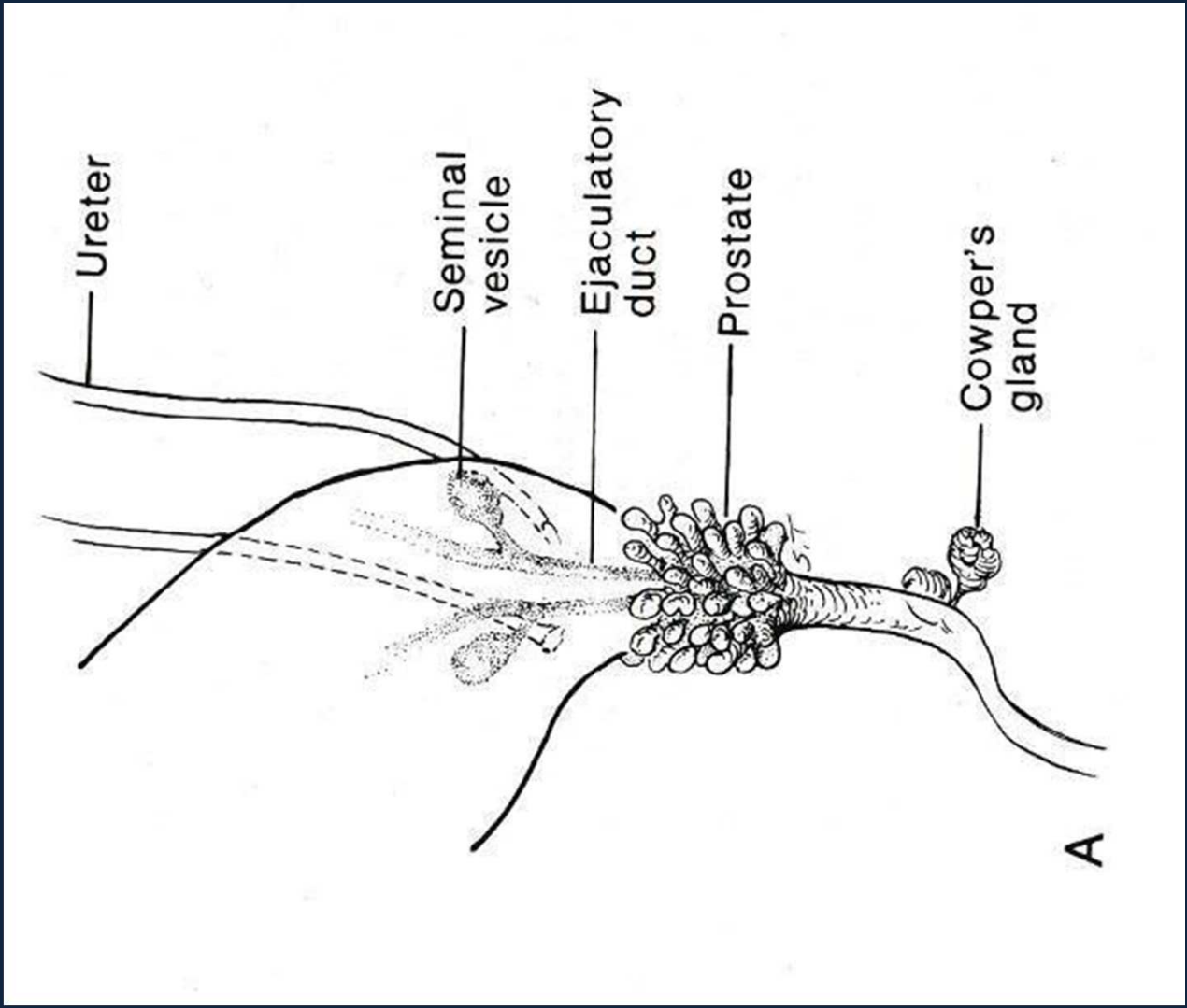
ΑΝΑΤΟΜΙΚΑ ΜΥΣΤΙΚΑ (ΚΑΙ...ΨΕΜΜΑΤΑ)

ΣΥΓΚΡΟΥΣΗ ΣΥΜΦΕΡΟΝΤΩΝ – Conflict of interest:

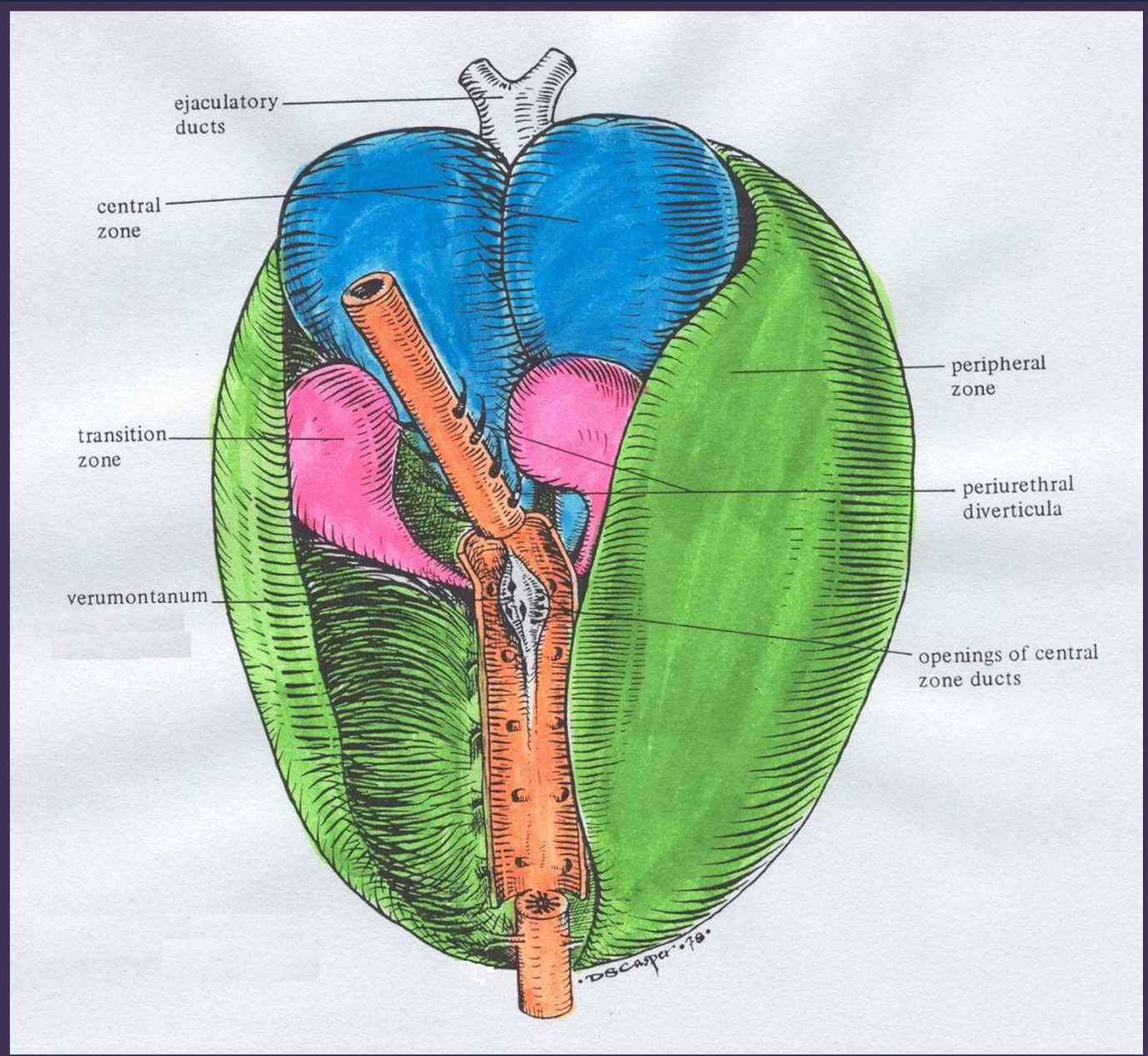
Κ. ΓΥΦΤΟΠΟΥΛΟΣ: ΚΑΜΜΙΑ

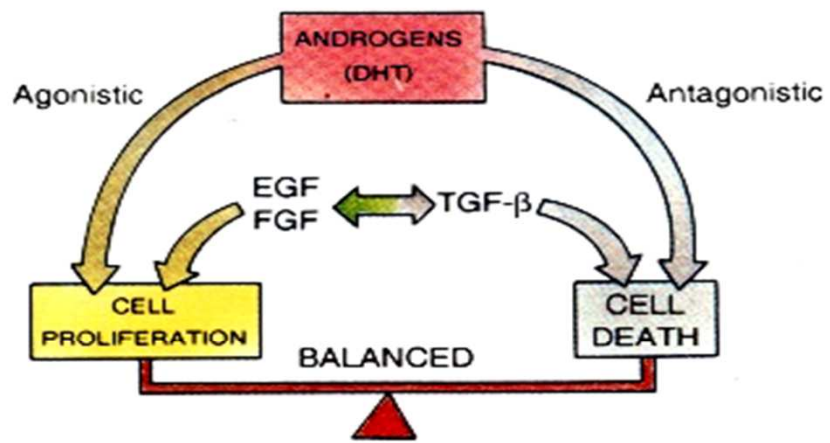
ΕΞΕΛΙΞΗ ΤΟΥ ΟΥΡΟΓΕΝΝΗΤΙΚΟΥ ΚΟΛΠΟΥ ΚΑΙ ΕΜΒΡΥΟΛΟΓΙΚΗ ΠΡΟΕΛΕΥΣΗ ΤΟΥ ΠΡΟΣΤΑΤΗ



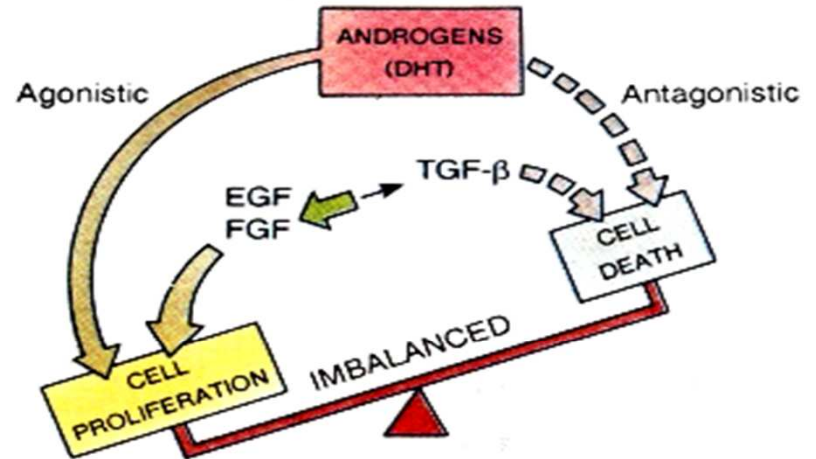


ΟΙ ΖΩΝΕΣ ΚΑΤΑ MC NEAL





NORMAL PROSTATE



PROSTATE OVERGROWTH

Oestrogens ?

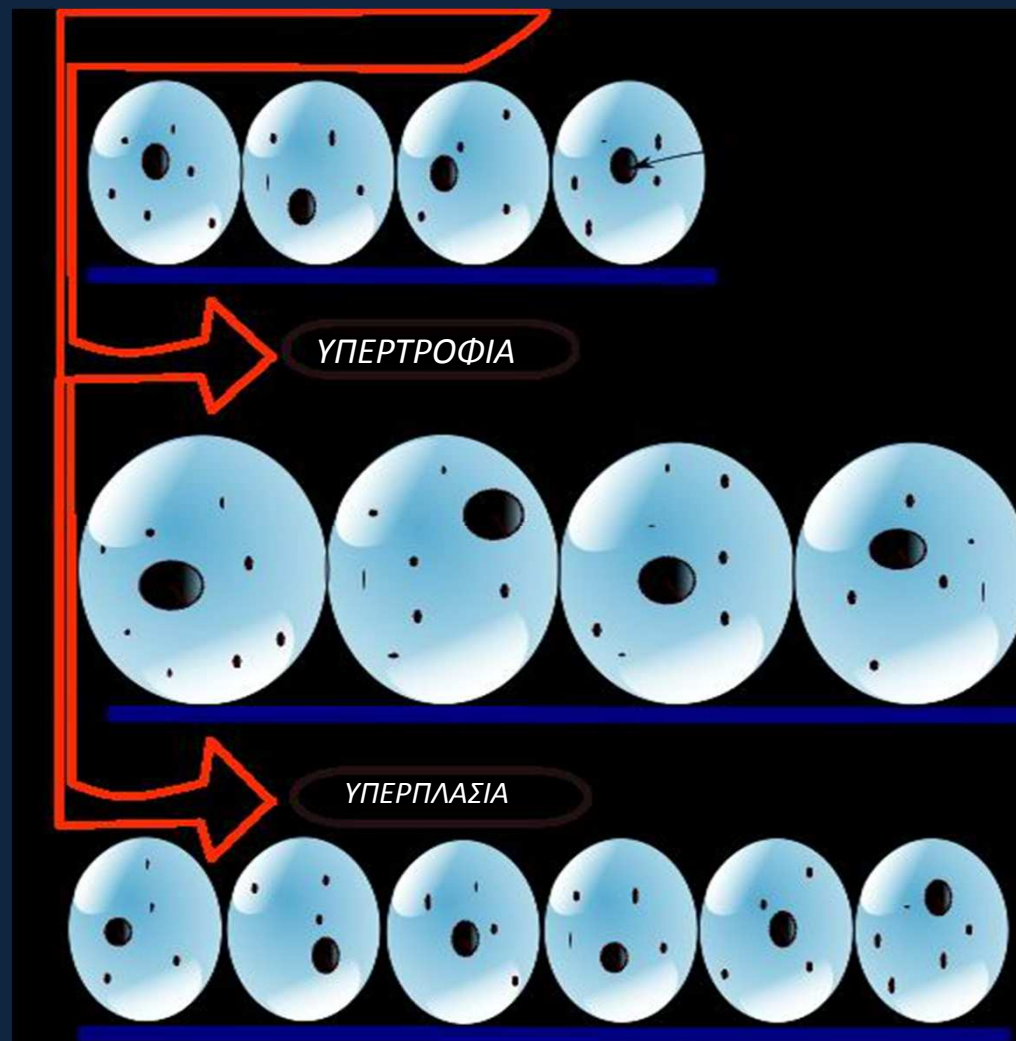
+

-

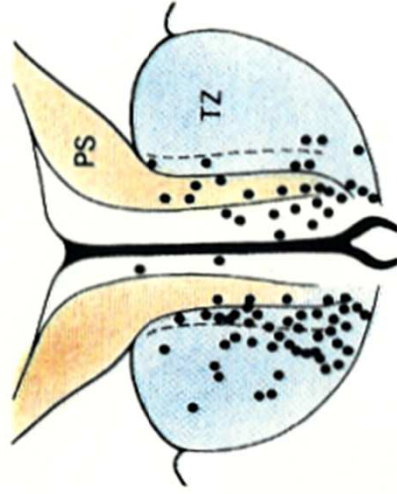
ER α

ER β

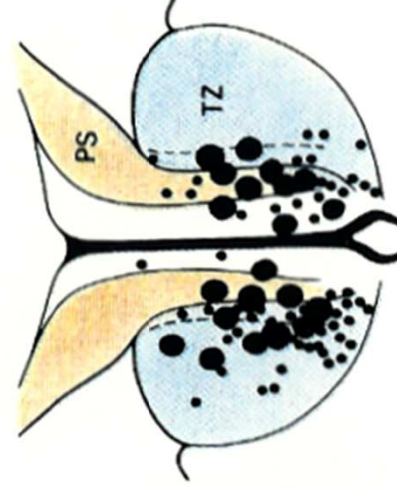
ΥΠΕΡΤΡΟΦΙΑ Η ΥΠΕΡΠΛΑΣΙΑ ΤΟΥ ΠΡΟΣΤΑΤΗ ???



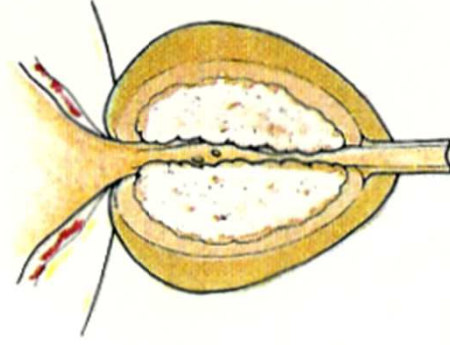
MICRONODULAR
HYPERPLASIA



NODULAR
GROWTH



CLINICAL BPH
(obstruction to urinary flow)



Oestrogens

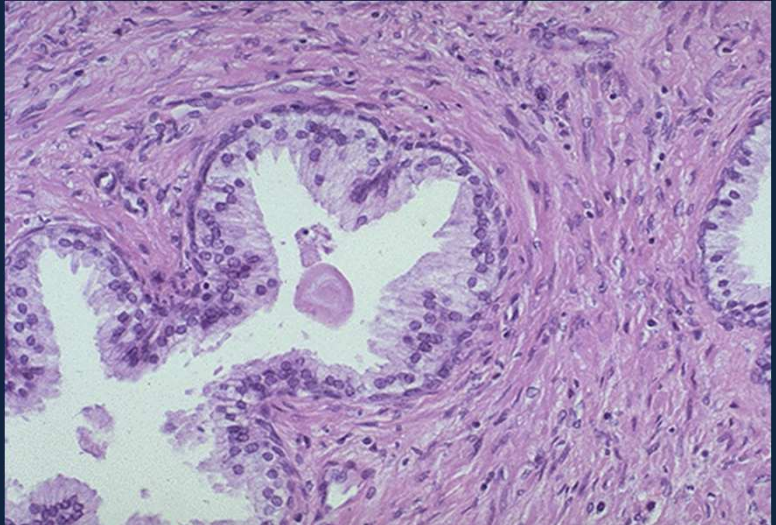
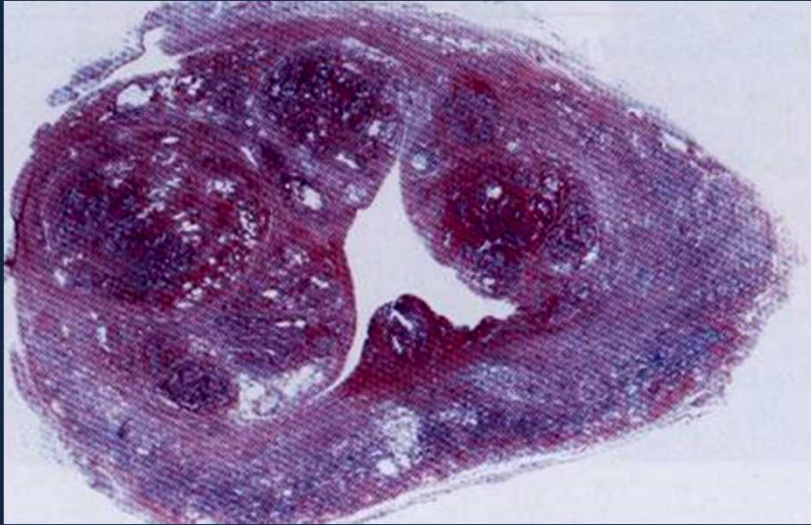
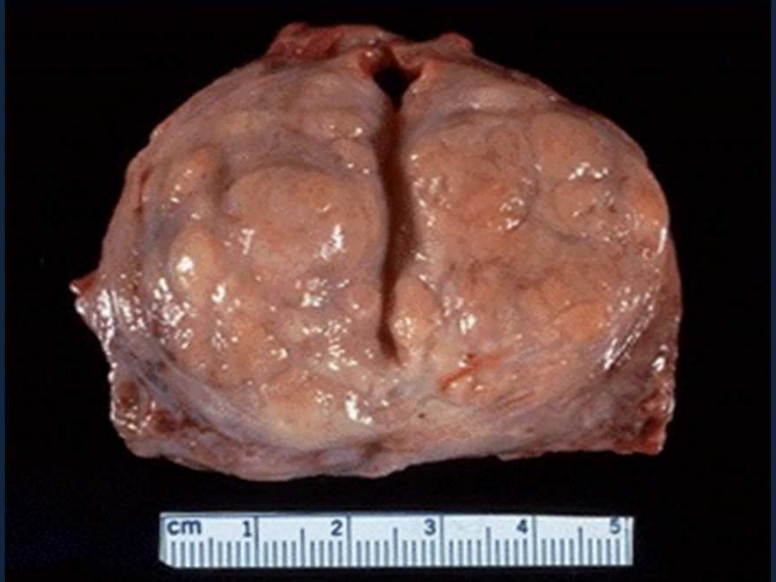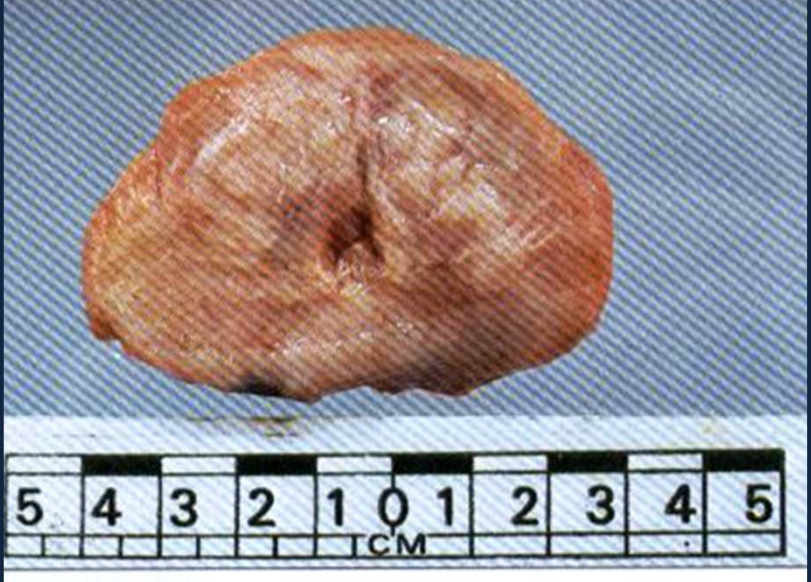
Imbalance of
growth regulatory factors

30y

50y

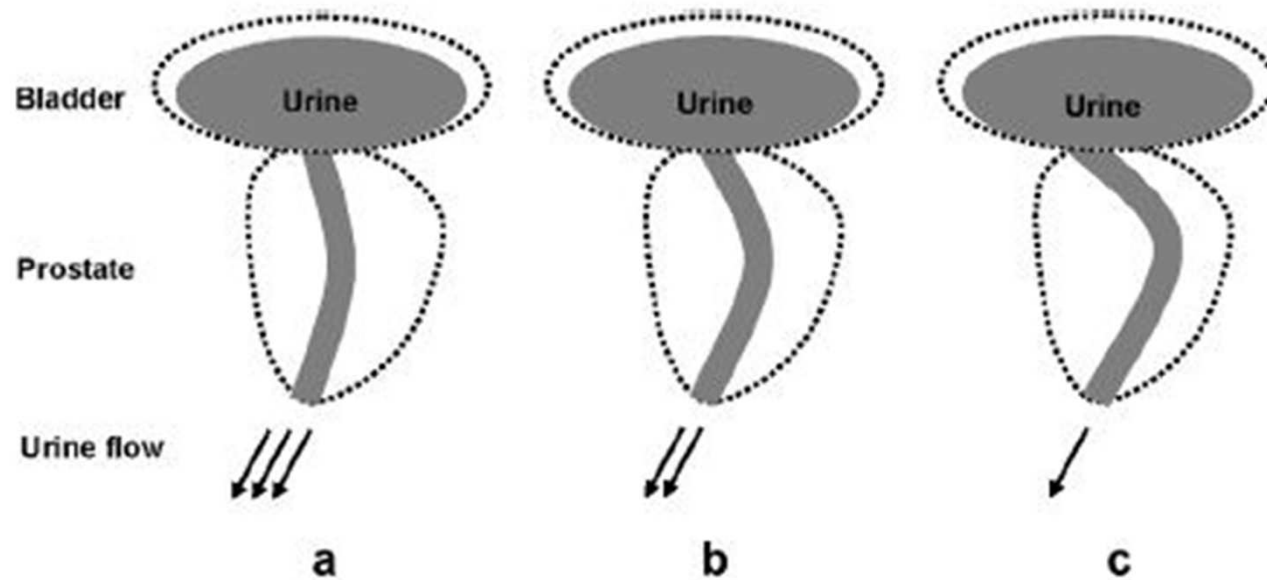
Change in
endocrine status

ΥΠΑΡΧΟΥΝ ΔΙΑΦΟΡΕΤΙΚΕΣ «ΜΟΡΦΕΣ» ΥΠΕΡΠΛΑΣΙΑΣ ΤΟΥ ΠΡΟΣΤΑΤΗ?

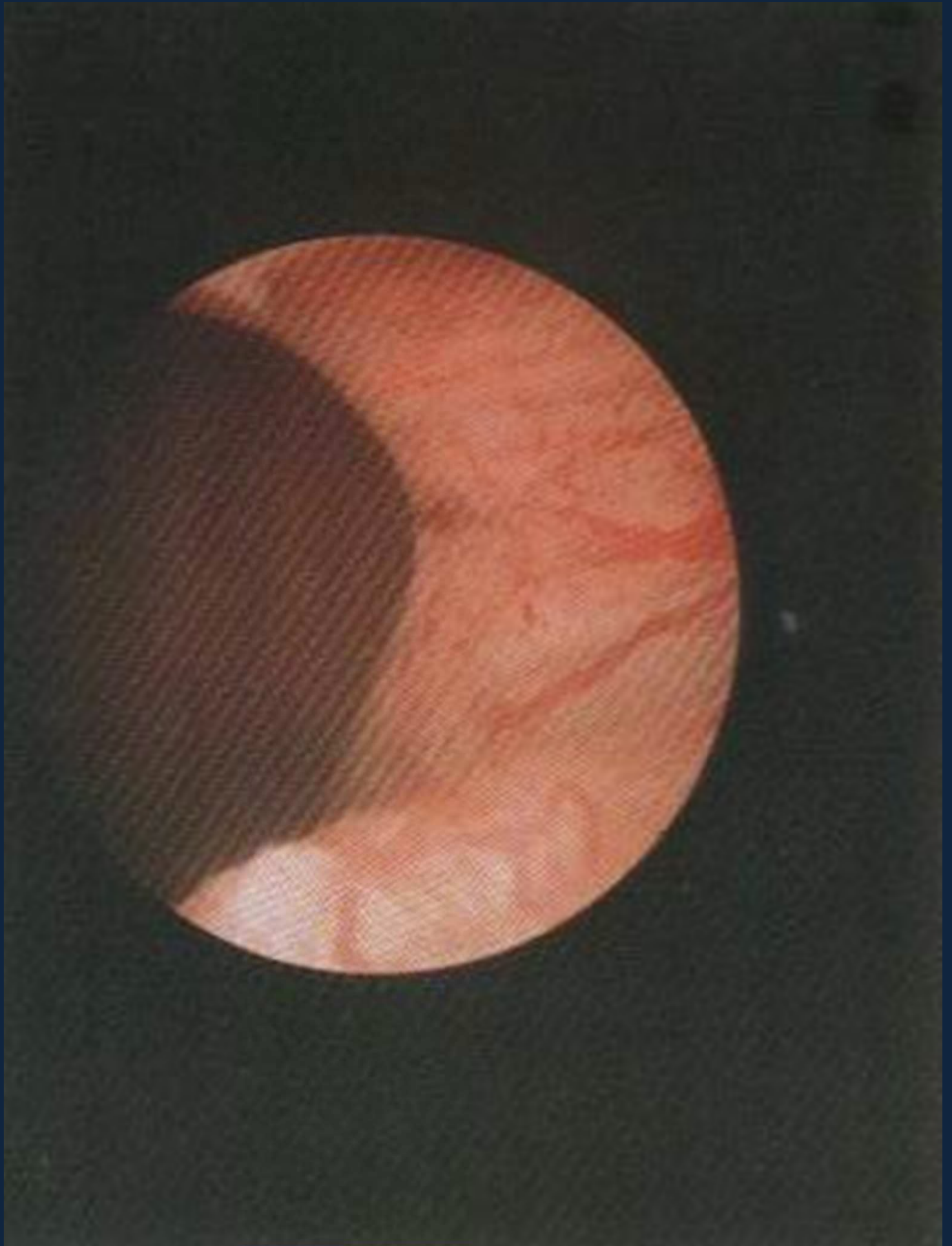


Ο «ΥΨΗΛΟΣ» ΑΥΧΕΝΑΣ

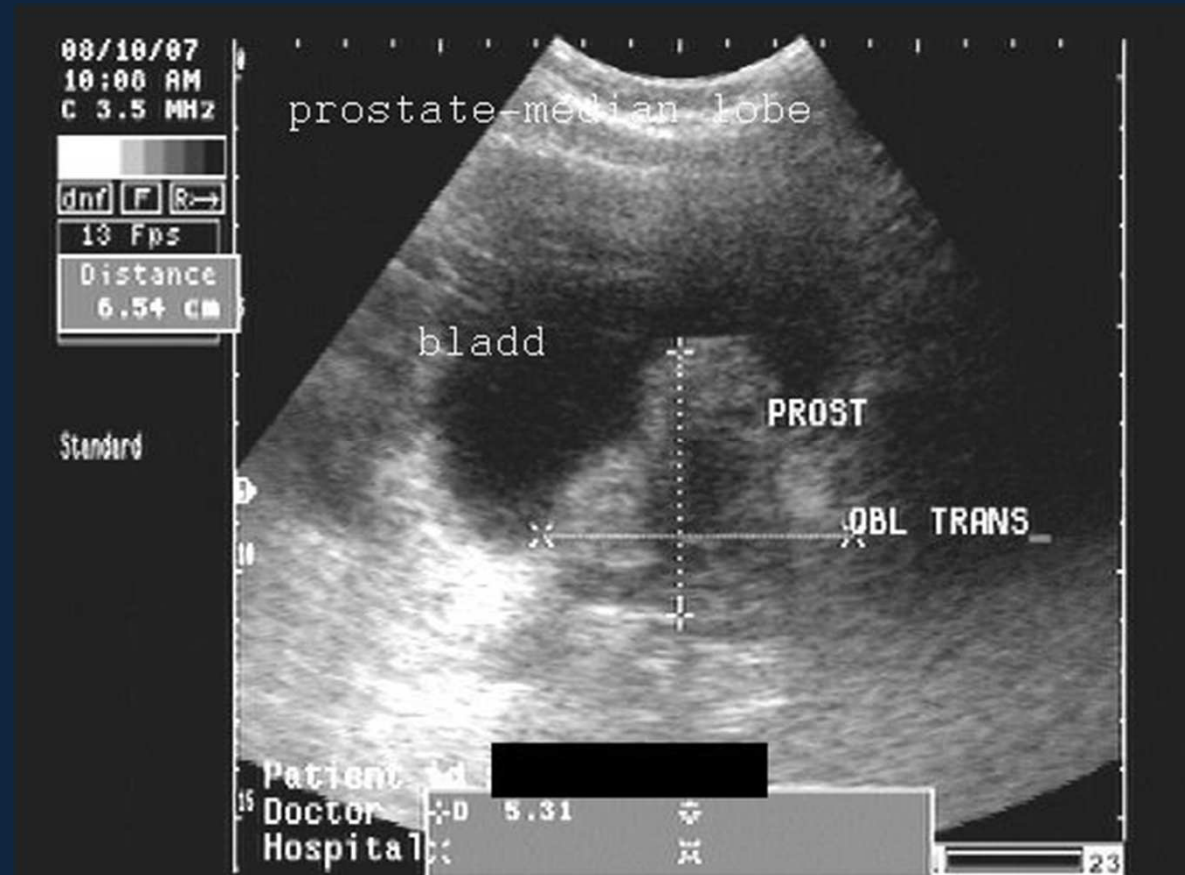The theory of Prostatic Urethra Angulation



Cho et al, Med Hypoth 2007



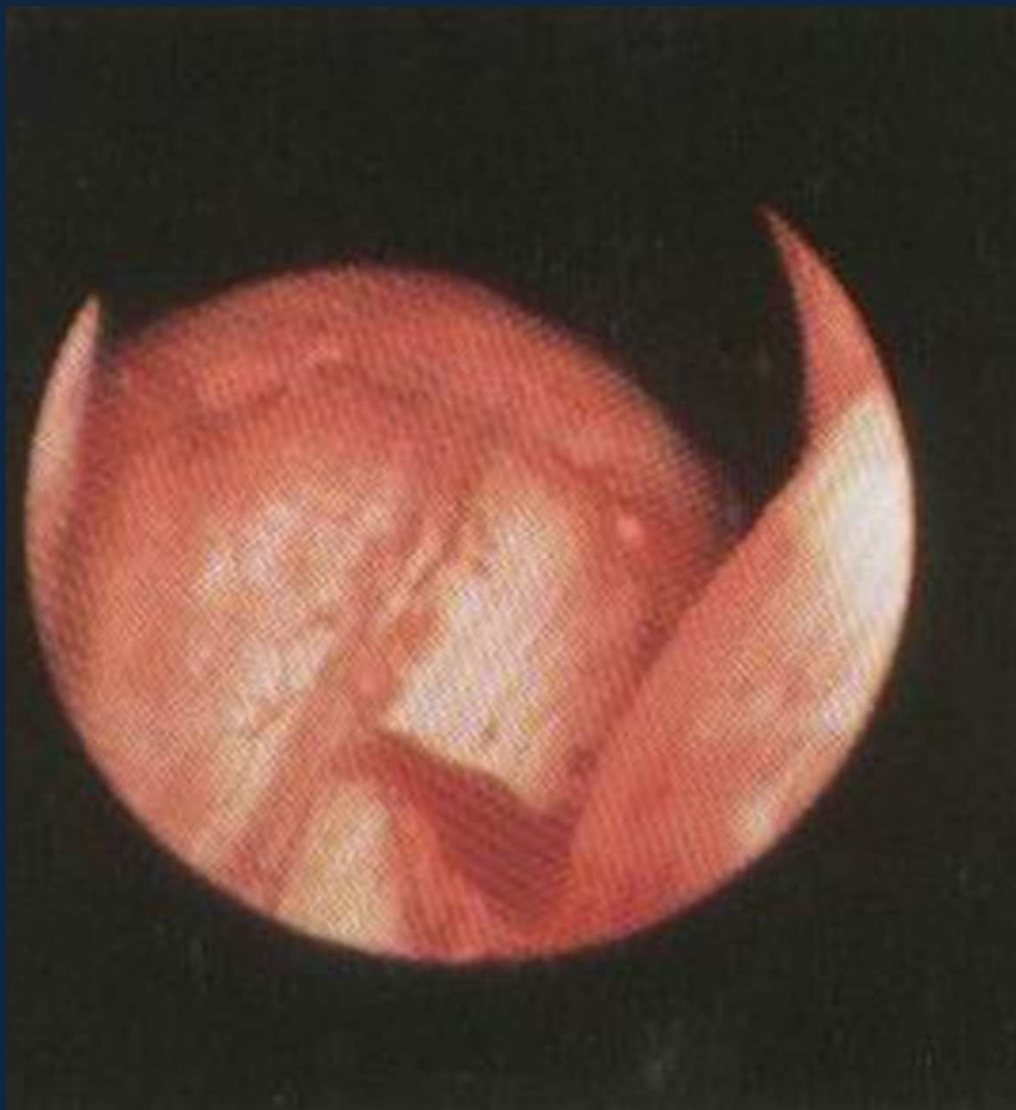Ο «ΜΕΣΟΣ» ΛΟΒΟΣ ???



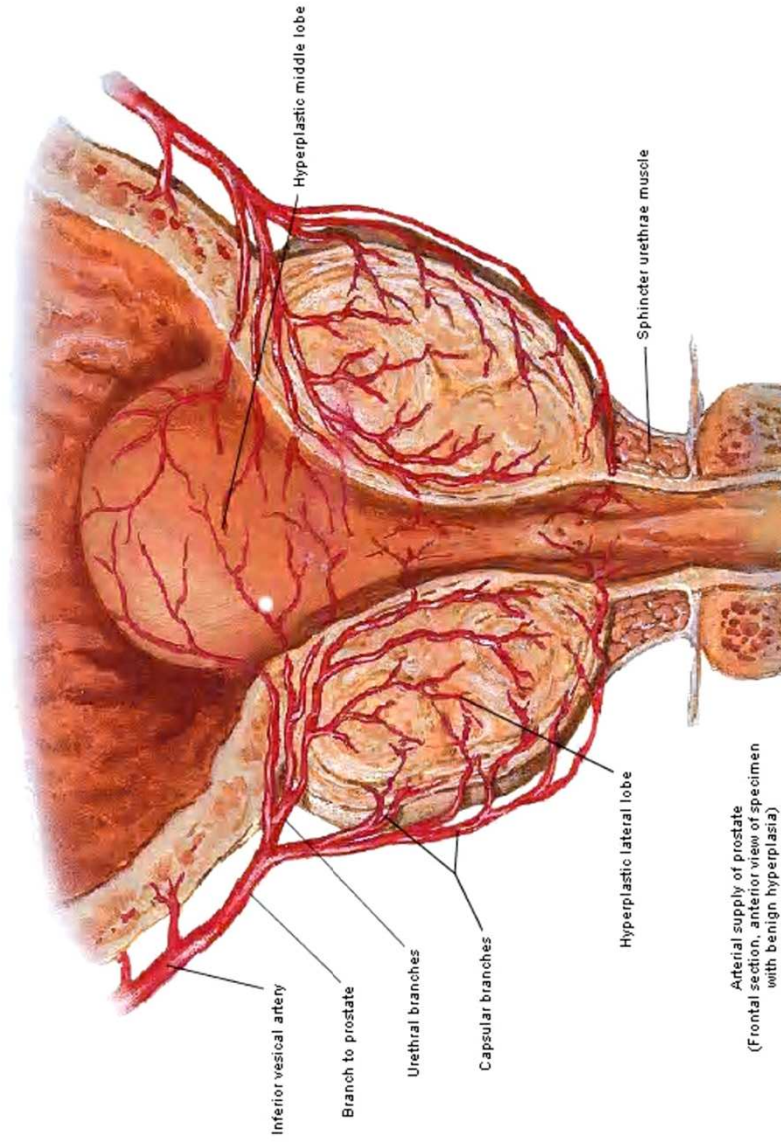
IPP: Intravesical Prostatic Protrusion

Chia et al BJU Int 2003

Ο «ΜΕΣΟΣ» ΛΟΒΟΣ ?????

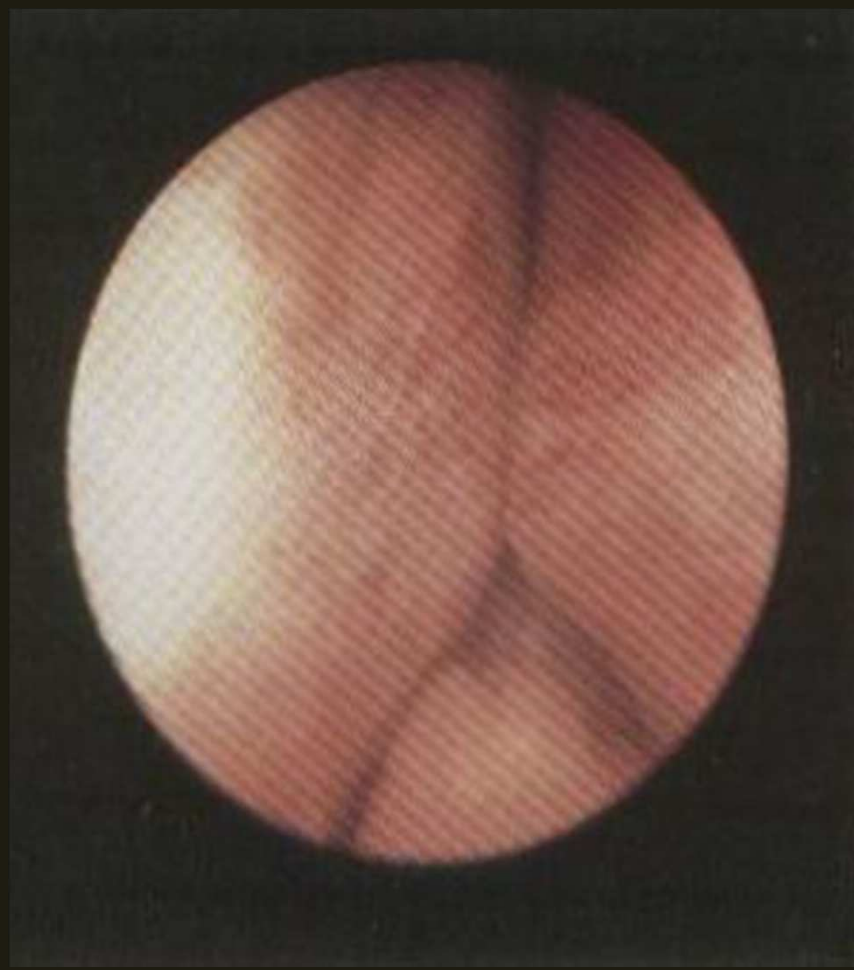
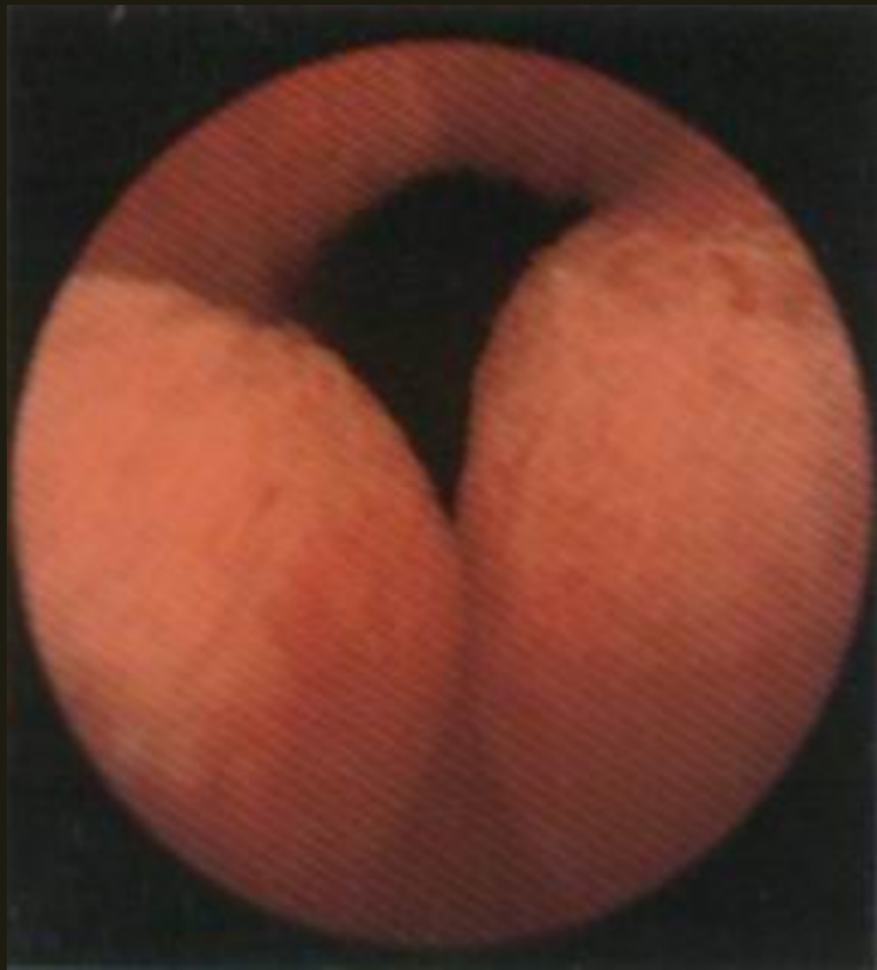

Arterial Supply of Prostate Benign Hyperplasia Specimen

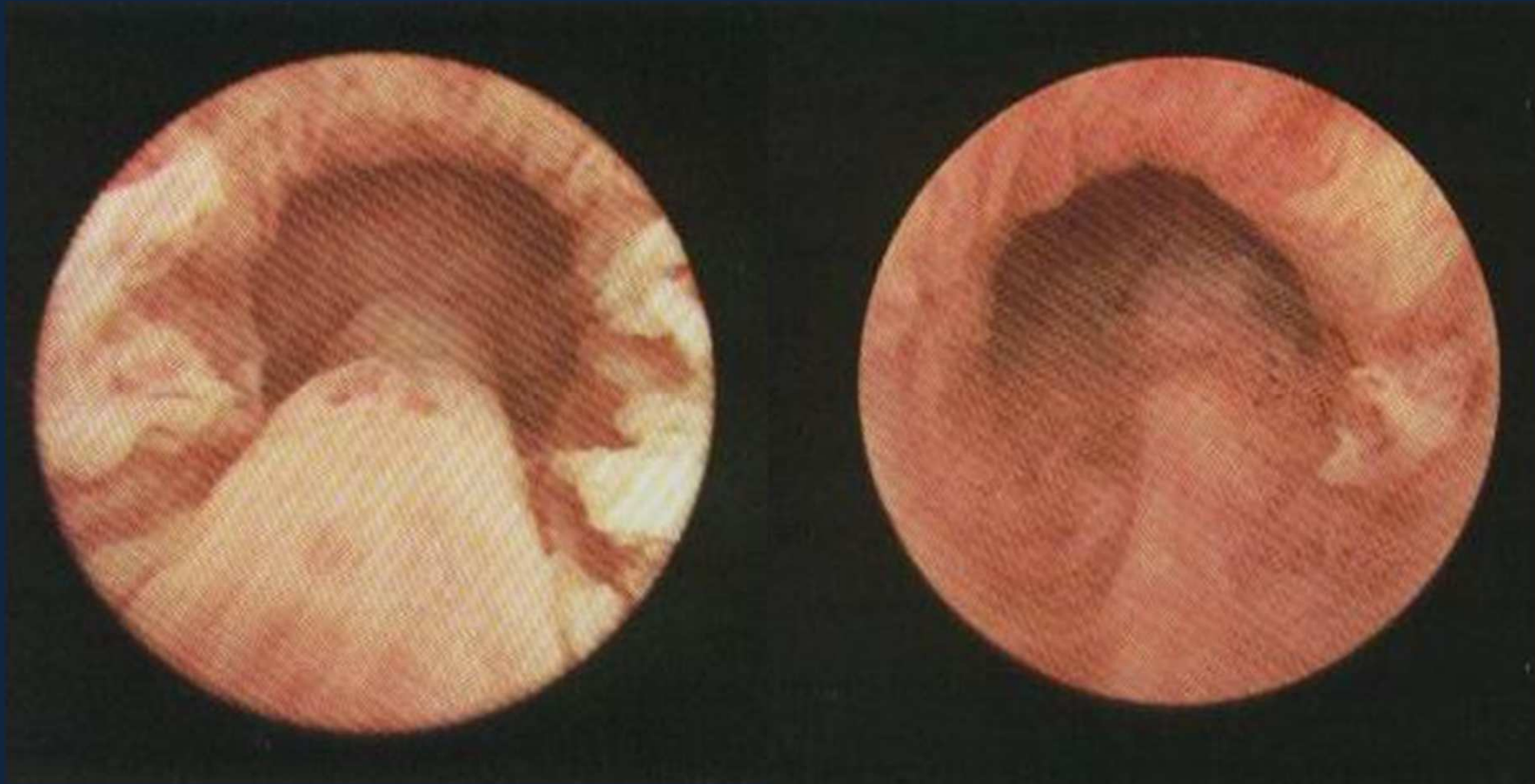


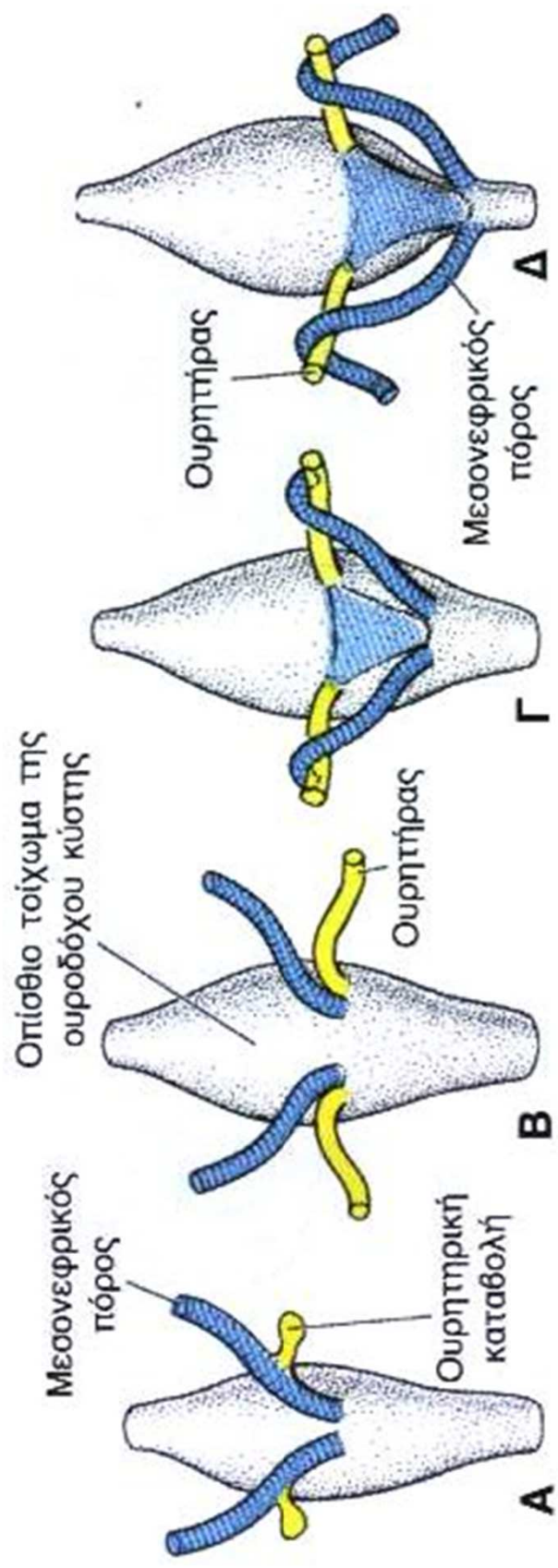
Arterial supply of prostate
(Frontal section, anterior view of specimen
with benign hyperplasia)

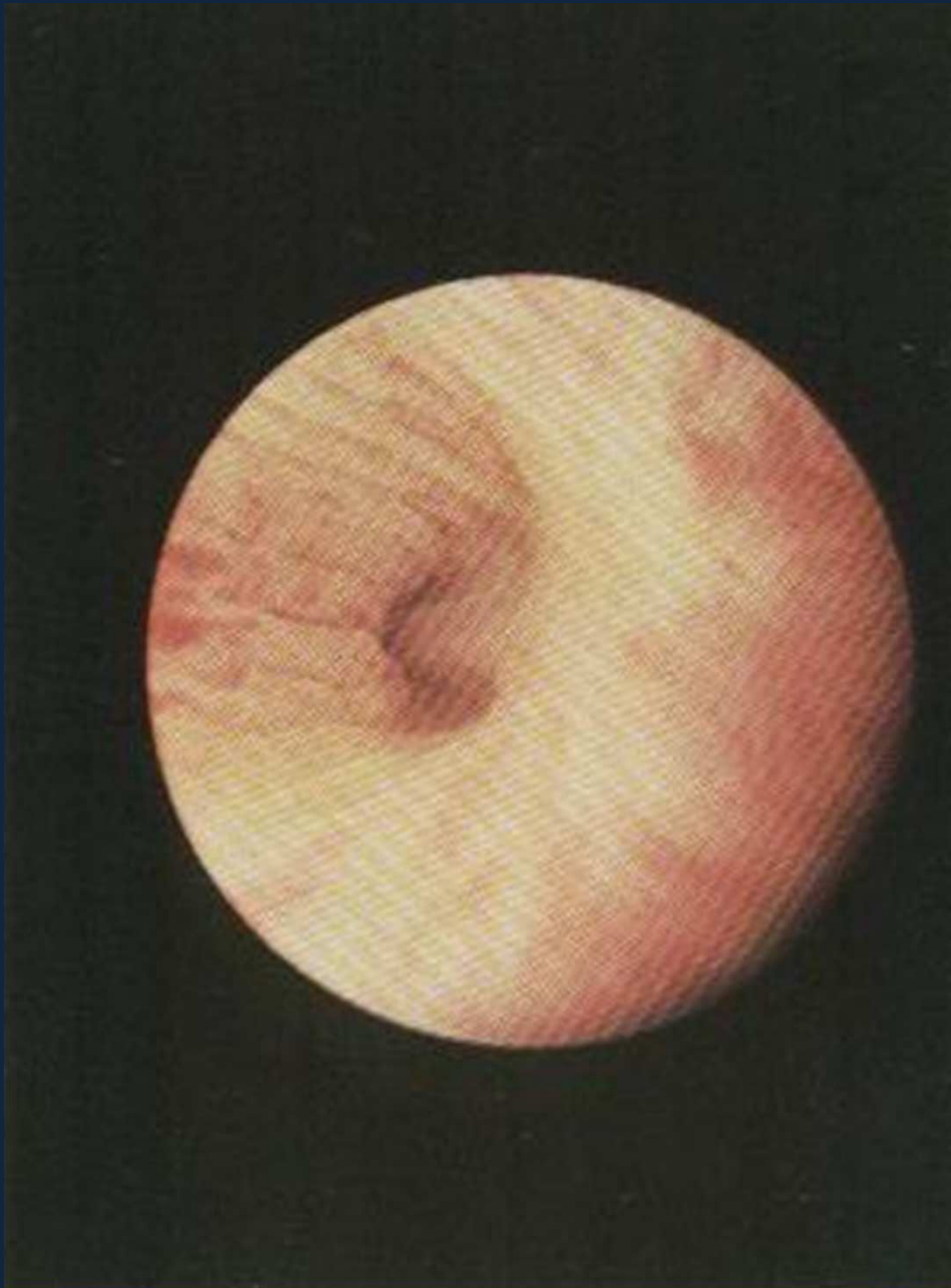
ΟΙ «ΠΛΑΓΙΟΙ» ΛΟΒΟΙ..... Η ΜΕΤΑΒΑΤΙΚΗ ΖΩΝΗ



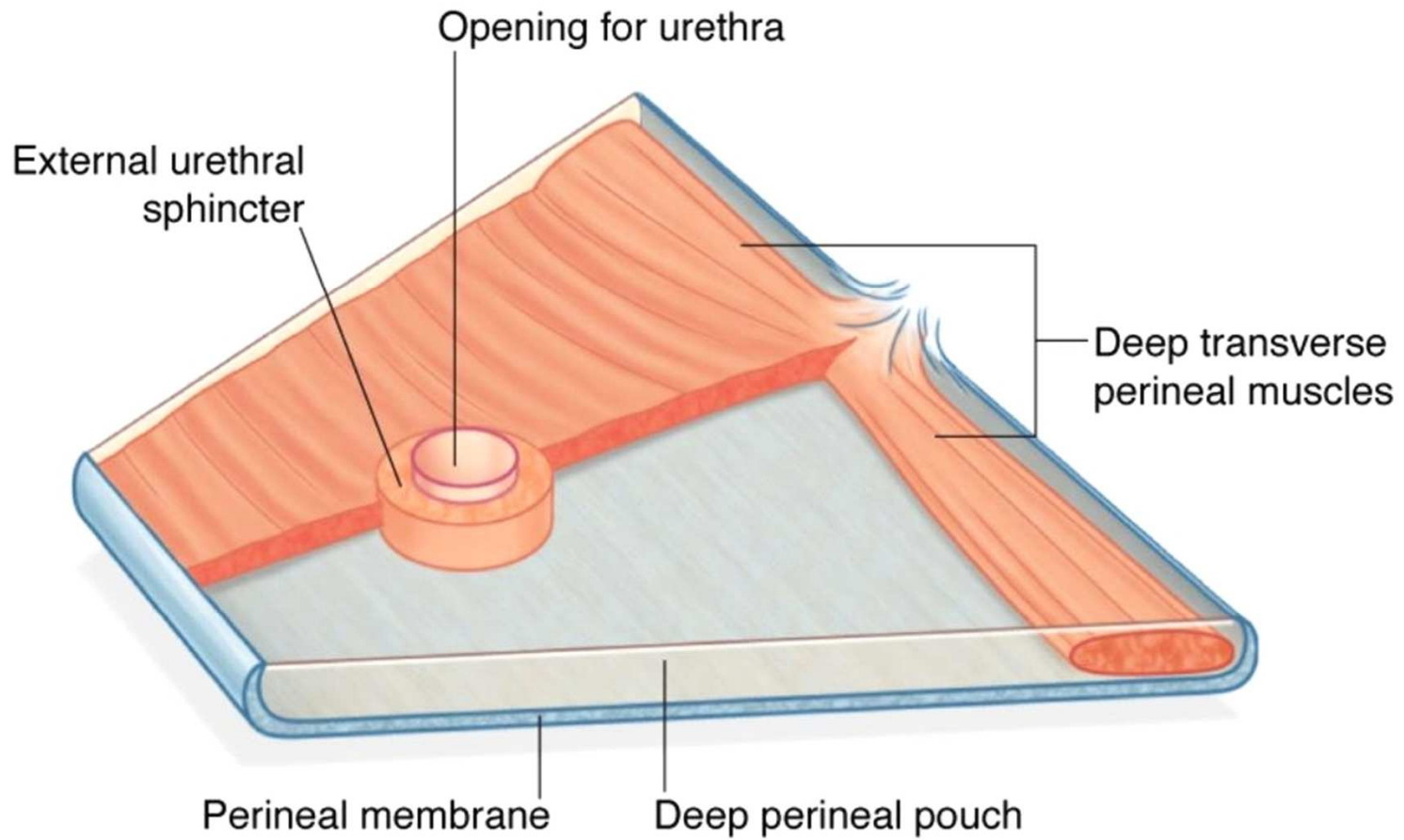
ΕΙΝΑΙ ΤΟ ΣΠΕΡΜΑΤΙΚΟ ΛΟΦΙΔΙΟ «ΟΡΙΟ» ΓΙΑ ΤΟΝ ΕΞΩ ΣΦΙΓΚΤΗΡΑ?



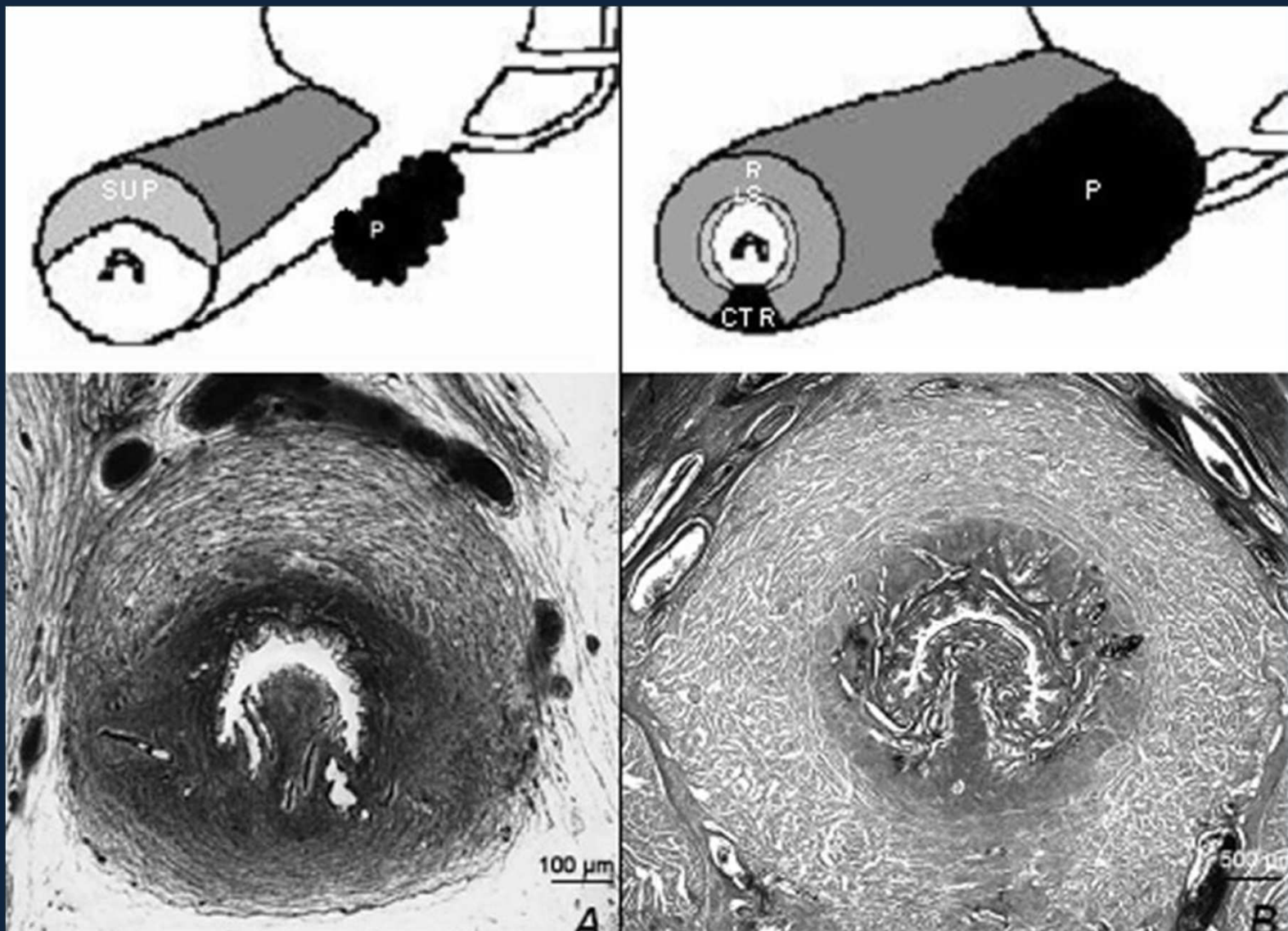


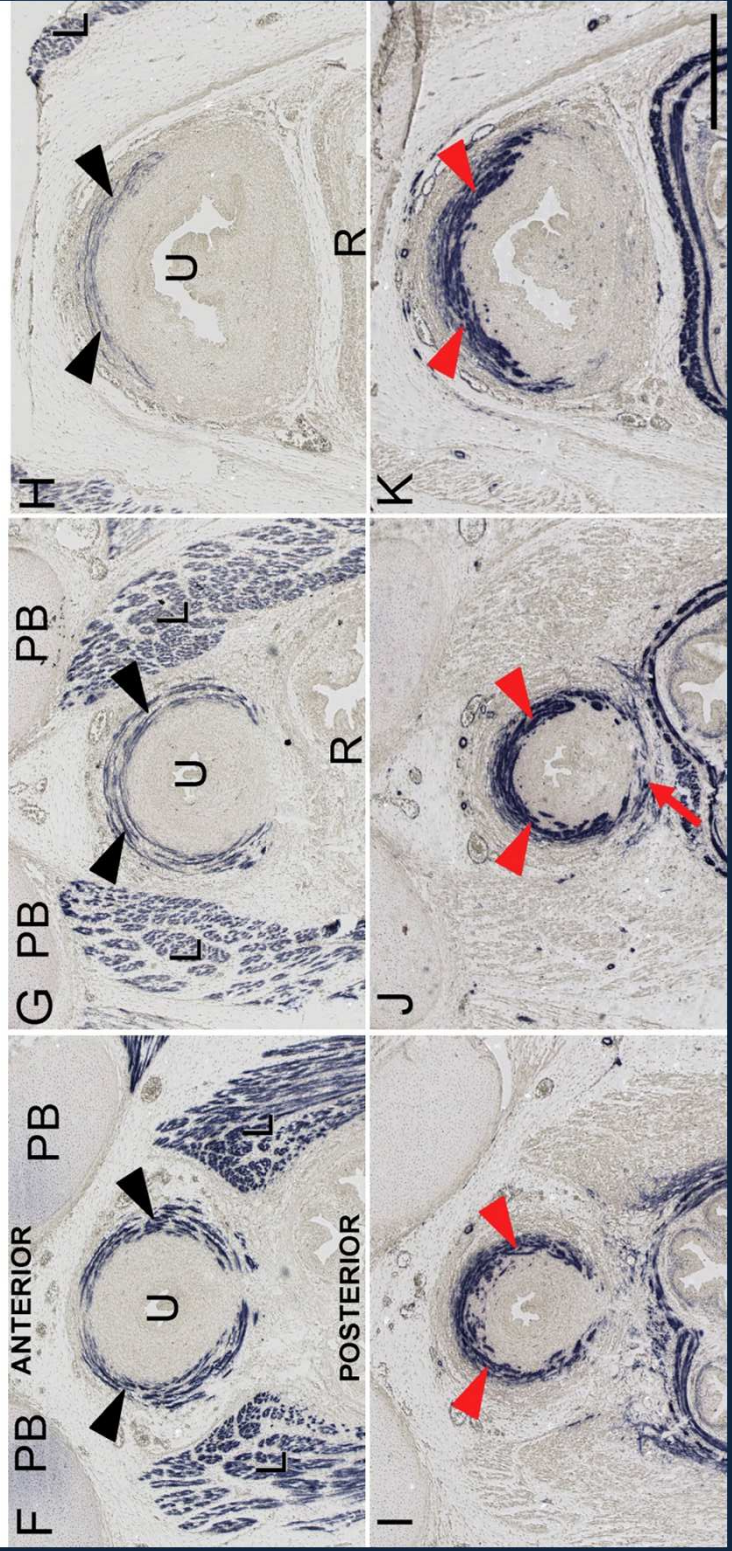
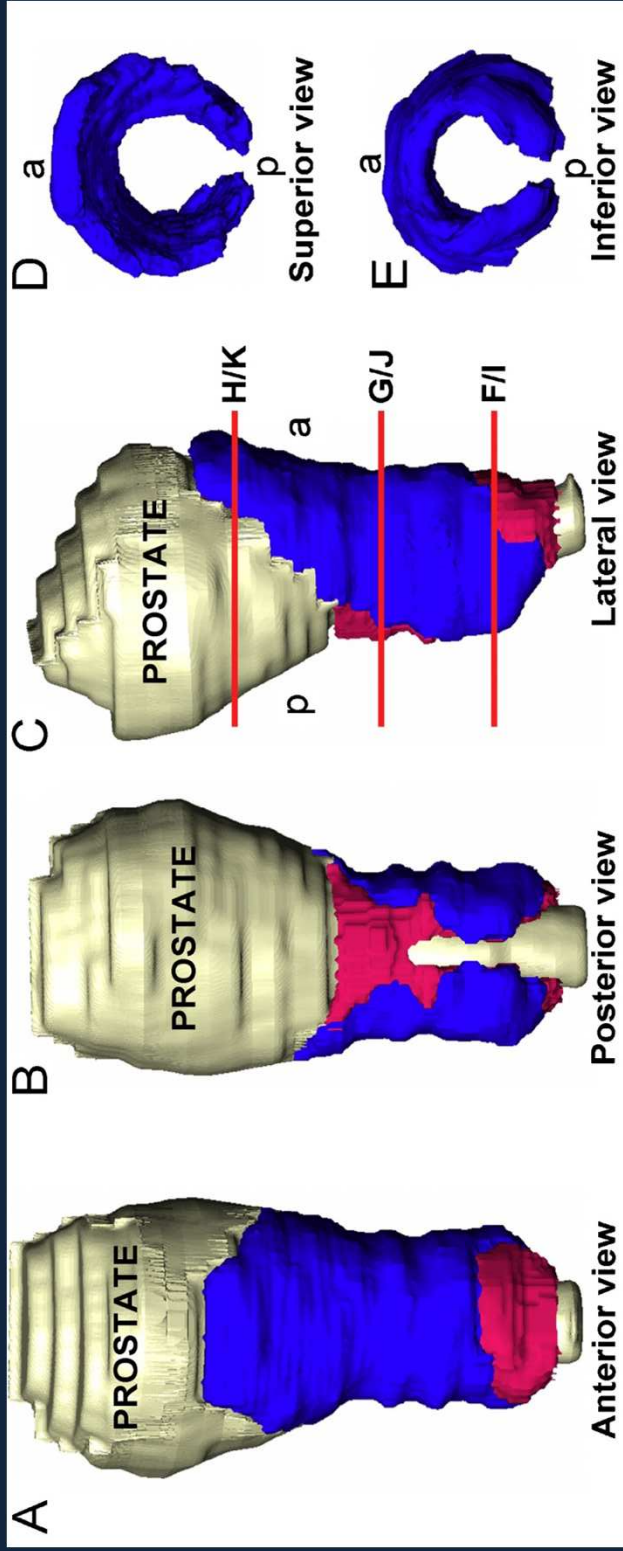


ΜΑ ΠΟΥ ΕΙΝΑΙ ΤΕΛΙΚΑ Ο ΕΞΩ ΣΦΙΓΚΤΗΡΑΣ ????

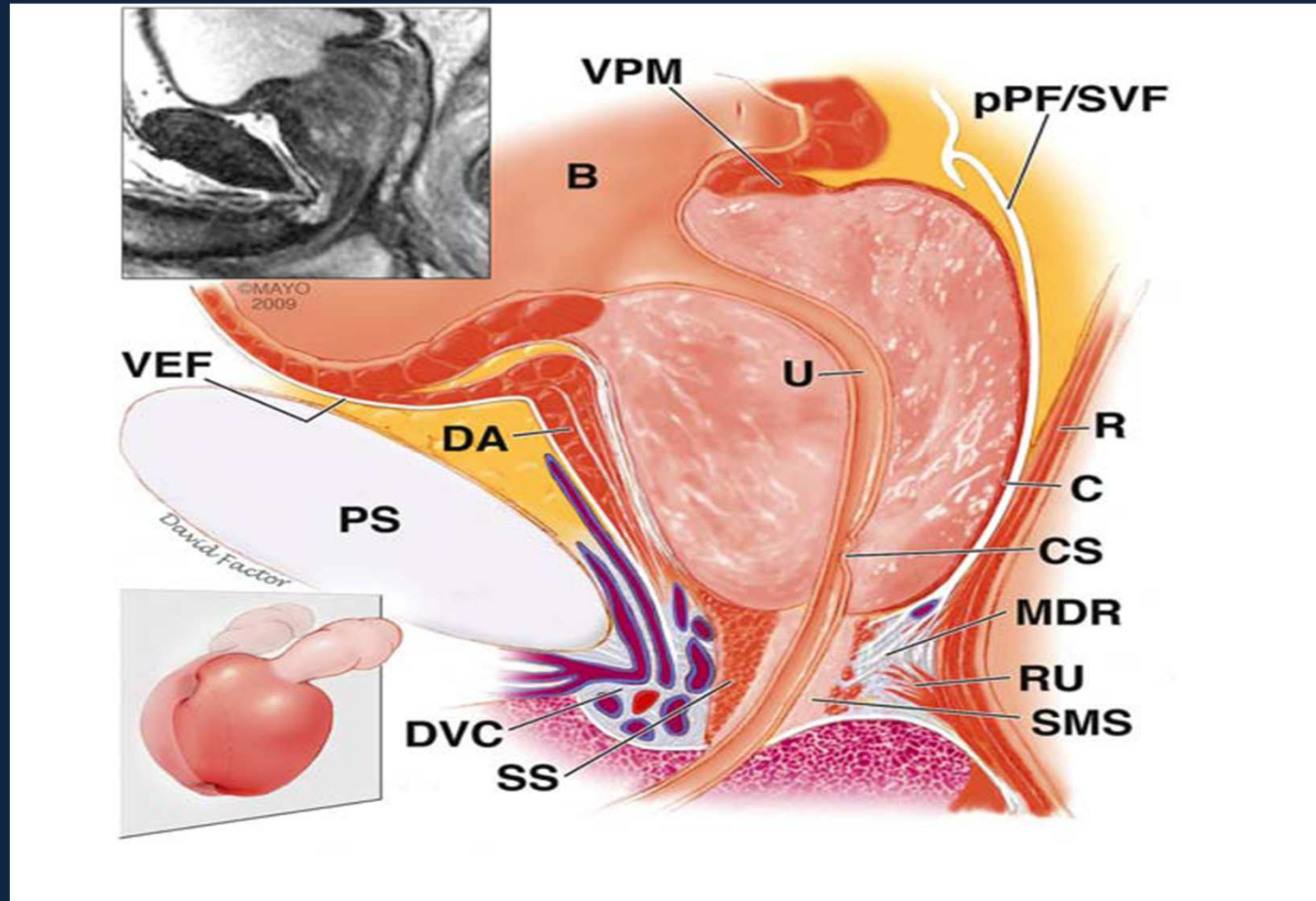


The urethral sphincter



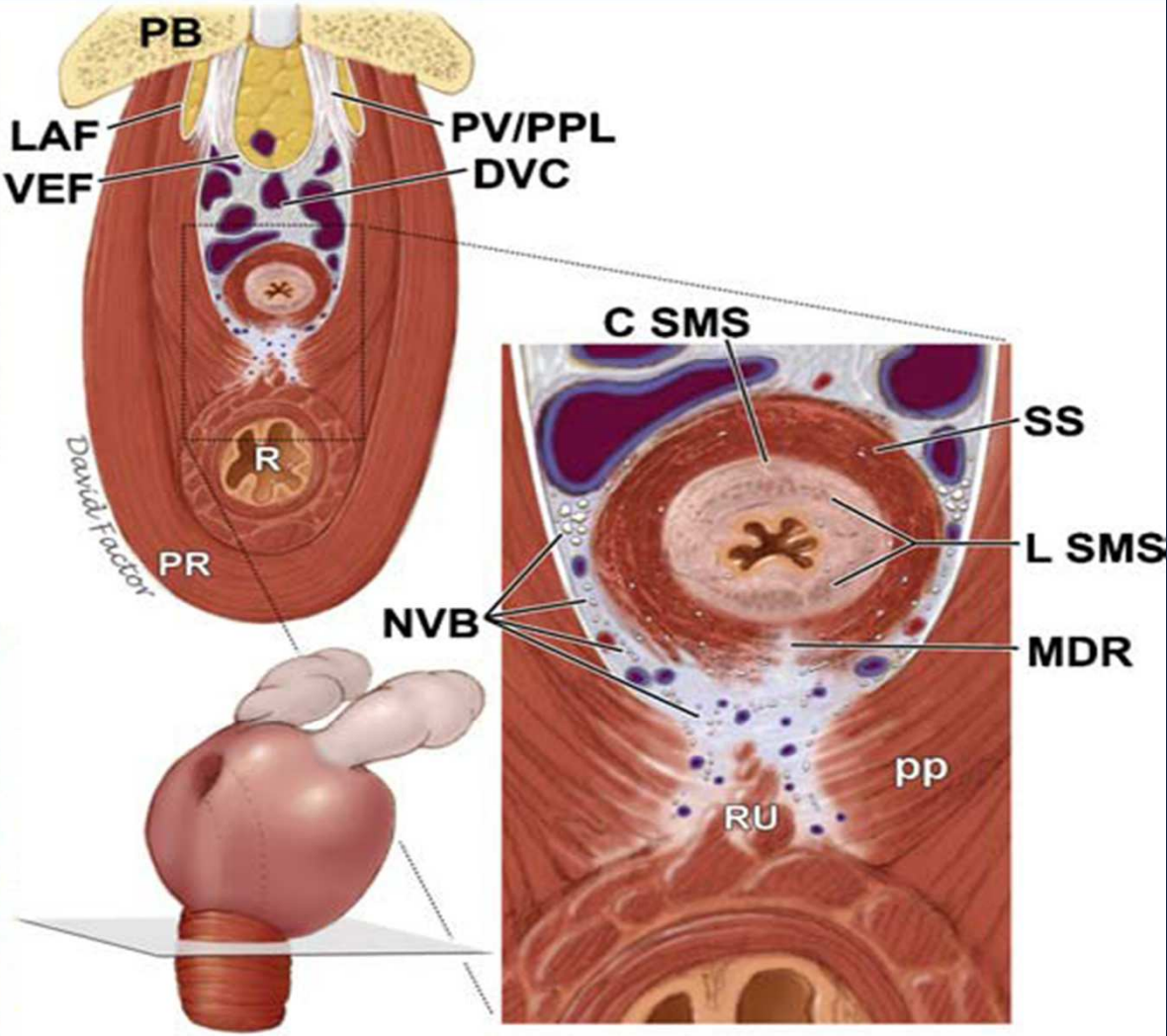
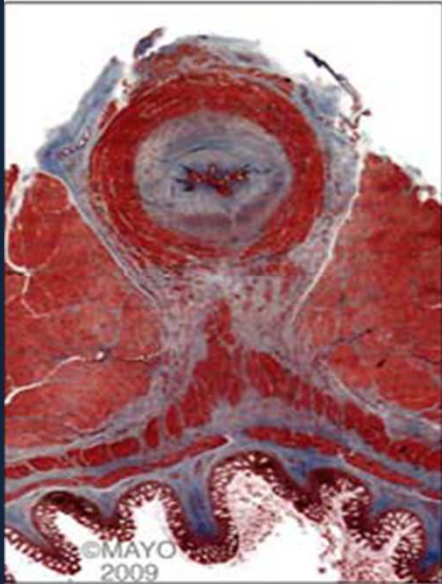
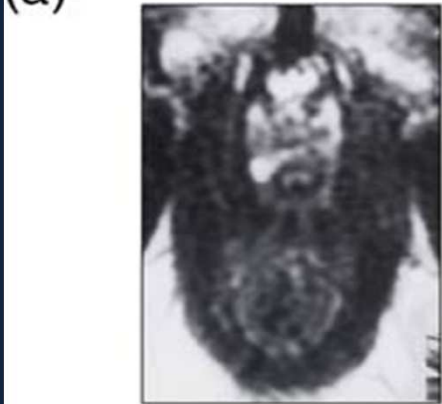

ΤΟ ΙΝΟΜΥΩΔΕΣ ΣΤΡΩΜΑ ΚΑΙ Η..ΠΟΔΙΑ (DETRUSOR APRON)

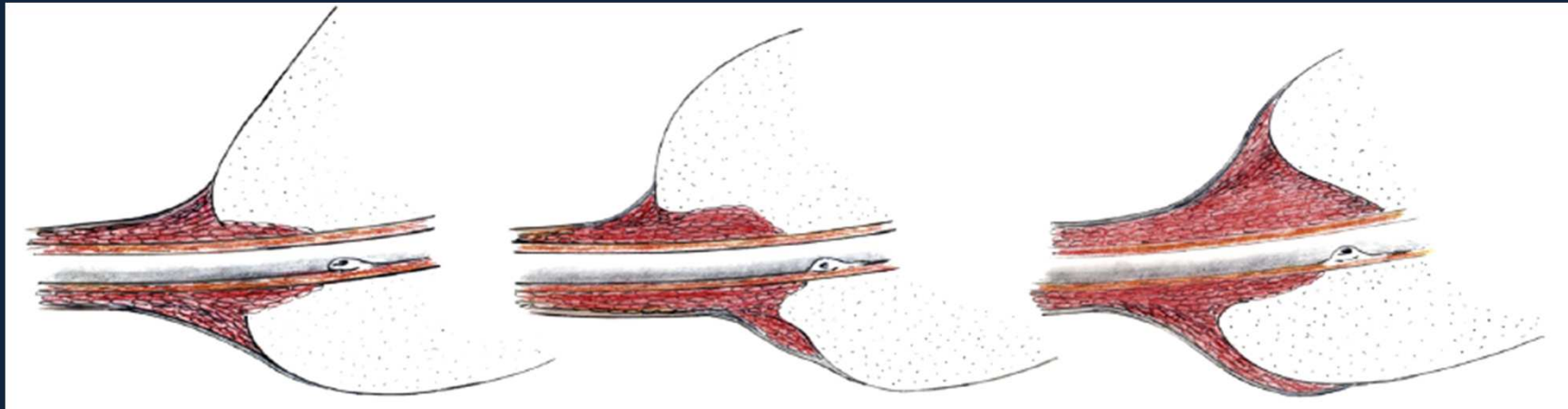
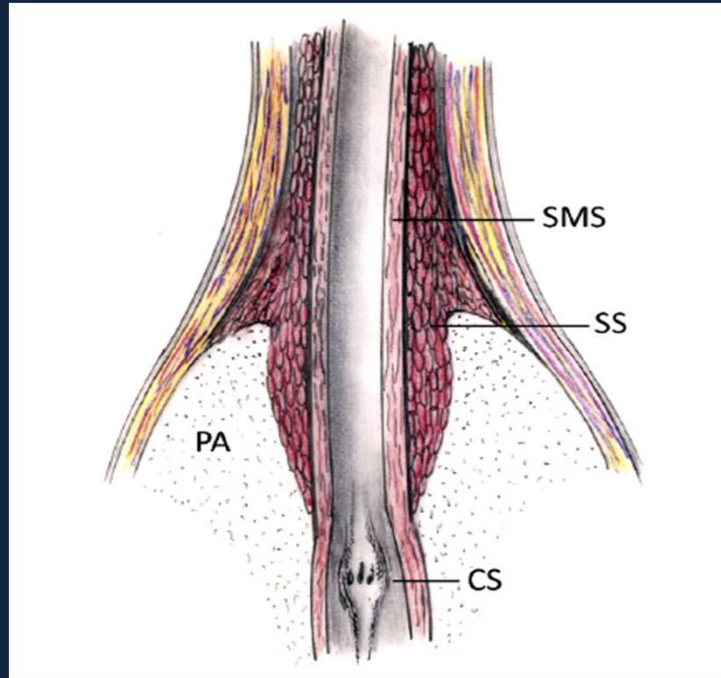


Ο (ΠΛΗΡΗΣ) ΣΦΙΓΚΤΗΡΙΑΚΟΣ ΜΗΧΑΝΙΣΜΟΣ...

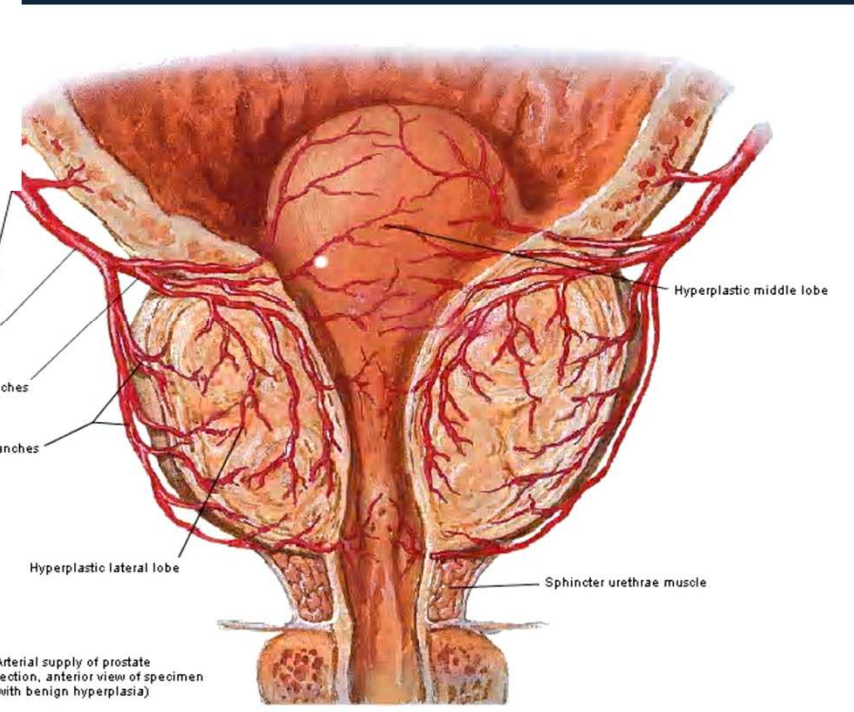
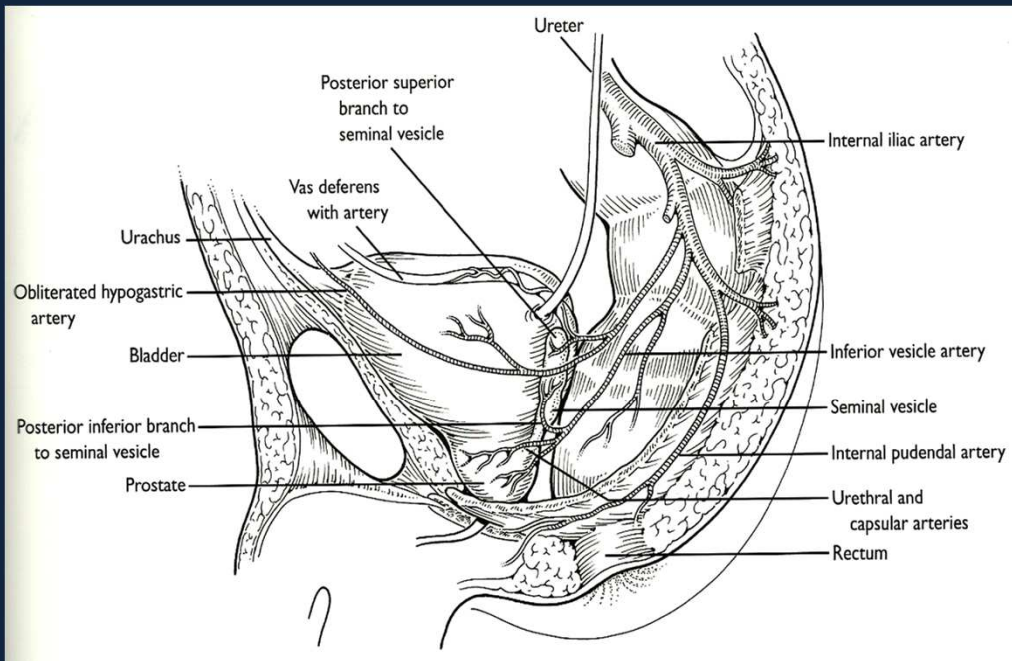
(a)



ΣΦΙΓΚΤΗΡΑΣ ΚΑΙ VERUMONTANUM...

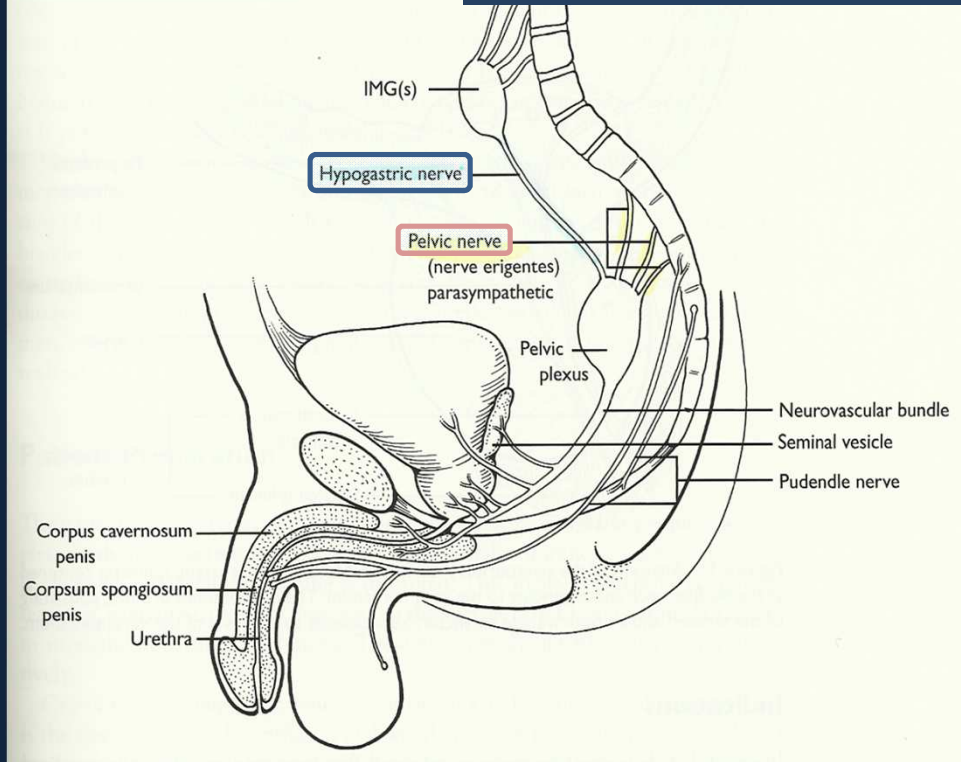


ΠΟΙΑ ΕΙΝΑΙ Η ΘΕΣΗ ΤΩΝ ΑΓΓΕΙΩΝ ΚΑΙ ΝΕΥΡΩΝ ?



- *Veru*
- *Apex*
- $3^{\circ} - 9^{\circ}$

ΝΕΥΡΩΣΗ ΣΦΙΓΚΤΗΡΙΑΚΟΥ ΜΗΧΑΝΙΣΜΟΥ



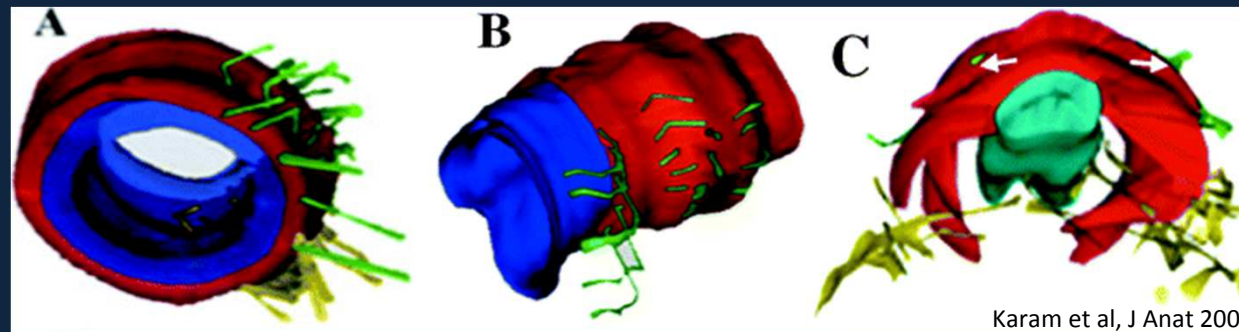
ΠΥΕΛΙΚΟ ΠΛΕΓΜΑ

(Pelvic plexus) 12-14
Λείος σφιγκτήρας

ΑΙΔΟΙΙΚΟ ΝΕΥΡΟ

(Pudendal nerve)
Ραβδο-σφιγκτήρας

Unmyelinated fibers: 5th-7th position
Myelinated fibers: 3th-9th position



ΣΗΡΑΓΓΩΔΗ ΝΕΥΡΑ (CAVERNOSAL NERVES) ???

ΠΑΧΙΑΙΑ ΝΕΥΡΑ (DORSAL PENILE NERVES) ???

ΠΟΙΟ ΕΙΝΑΙ ΤΟ ΦΥΣΙΟΛΟΓΙΚΟ ΜΗΚΟΣ ΚΑΙ ΕΥΡΟΣ ΤΗΣ ΟΥΡΗΘΡΑΣ ??

