



European Association of Urology



Review – Testis Cancer

European Consensus Conference on Diagnosis and Treatment of Germ Cell Cancer: A Report of the Second Meeting of the European Germ Cell Cancer Consensus group (EGCCCG): Part I

Susanne Krege^{1,*}, Jörg Beyer², Rainer Souchon³, Peter Albers⁴, Walter Albrecht⁵, Ferran Algaba⁶, Michael Bamberg⁷, István Bodrogi⁸, Carsten Bokemeyer⁹, Eva Cavallin-Ståhl¹⁰, Johannes Classen¹¹, Christoph Clemm¹², Gabriella Cohn-Cedermark¹³, Stéphane Culine¹⁴, Gedske Daugaard¹⁵, Pieter H.M. De Mulder¹⁶, Maria De Santis¹⁷, Maike de Wit¹⁸, Ronald de Wit¹⁹, Hans Günter Derigs²⁰, Klaus-Peter Dieckmann²¹, Annette Dieing²², Jean-Pierre Droz²³, Martin Fenner²⁴, Karim Fizazi²⁵, Aude Flechon²⁶, Sophie D. Fosså²⁷, Xavier Garcia del Muro²⁸, Thomas Gauler²⁹, Lajos Geczi³⁰, Arthur Gerl³¹, Jose Ramon Germa-Lluch³², Silke Gillessen³³, Jörg T. Hartmann³⁴, Michael Hartmann³⁵, Axel Heidenreich³⁶, Wolfgang Hoeltl³⁷, Alan Horwich³⁸, Robert Huddart³⁹, Michael Jewett⁴⁰, Johnathan Joffe⁴¹, William G. Jones⁴², László Kisbenedek⁴³, Olbjørn Klepp⁴⁴, Sabine Kliesch⁴⁵, Kai Uwe Koehrmann⁴⁶, Christian Kollmannsberger⁴⁷, Markus Kuczyk⁴⁸, Pilar Laguna⁴⁹, Oscar Leiva Galvis⁵⁰, Volker Loy⁵¹, Malcolm D. Mason⁵², Graham M. Mead⁵³, Rolf Mueller⁵⁴, Craig Nichols⁵⁵, Nicola Nicolai⁵⁶, Tim Oliver⁵⁷, Dalibor Ondrus⁵⁸, Gosse O.N. Oosterhof⁵⁹, Luis Paz Ares⁶⁰, Giorgio Pizzocaro⁶¹, Jörg Pont⁶², Tobias Pottek⁶³, Tom Powles⁶⁴, Oliver Rick⁶⁵, Giovanni Rosti⁶⁶, Roberto Salvioni⁶⁷, Jutta Scheiderbauer⁶⁸, Hans-Ulrich Schmelz⁶⁹, Heinz Schmidberger⁷⁰, Hans-Joachim Schmoll⁷¹, Mark Schrader⁷², Felix Sedlmayer⁷³, Niels E. Skakkebaek⁷⁴, Aslam Sohaib⁷⁵, Sergei Tjulandin⁷⁶, Pdraig Warde⁷⁷, Stefan Weinknecht⁷⁸, Lothar Weissbach⁷⁹, Christian Wittekind⁸⁰, Eva Winter⁸¹, Lori Wood⁸², Hans von der Maase⁸³

¹Department of Urology, Krankenhaus Maria-Hilf, Krefeld, Germany

²Department of Hemato-Oncology, Vivantes Klinikum Am Urban, Berlin, Germany

³Department of Radiooncology, Allg. Krankenhaus, Hagen, Germany

⁴Department of Urology, Klinikum Kassel, Germany

⁵Department of Urology, Rudolfstiftung, Vienna, Austria

⁶Department of Pathology, Fundacion Puigvert, Barcelona, Spain

⁷Department of Radiooncology, Universität Tübingen, Germany

⁸National Institute of Oncology, Chemotherapy and Clinical Pharmacology, Budapest, Hungary

⁹Department of Hemato-Oncology, Universität Hamburg, Germany

¹⁰Department of Oncology, University Hospital Lund, Sweden

¹¹Department of Radiooncology, St. Vincentius Kliniken, Karlsruhe, Germany

¹²Department of Oncology, Klinikum rechts der Isar, München, Germany

- ¹³ Department of Oncology-Pathology, Radiumhemmet Karolinska Hospital, Stockholm, Sweden
- ¹⁴ Department of Oncology, CRLC Val d'Aurelle, Montpellier, France
- ¹⁵ Department of Oncology, Rigshospitalet, Finsen Center, Copenhagen, Denmark
- ¹⁶ Department of Internal Medicine, Oncology, University Hospital Nijmegen, The Netherlands
- ¹⁷ Department of Oncology, Kaiser St. Josef Hospital, Vienna, Austria
- ¹⁸ Department of Hemato-Oncology, Krankenhaus Neukölln, Berlin, Germany
- ¹⁹ Department of Medical Oncology, Erasmus University Medical Center, Rotterdam, The Netherlands
- ²⁰ Department of Hemato-Oncology, Städt. Kliniken, Frankfurt, Germany
- ²¹ Department of Urology, Albertinen-Hospital, Hamburg, Germany
- ²² Department of Hemato-Oncology, Universität Charité Mitte, Berlin, Germany
- ²³ Department of Oncology, Medical Centre Leon Berard, Lyon, France
- ²⁴ Department of Hemato-Oncology, Universität Hannover, Germany
- ²⁵ Department of Hemato-Oncology, Institute Gustave Roussy, Villejuif, France
- ²⁶ Department of Medical Oncology, Centre Leon Berard, Lyon, France
- ²⁷ Department of Radiooncology, The Norwegian Radium Hospital, Oslo, Norway
- ²⁸ Department of Oncologia Medica, Hospital Furan 1 Reynals, Hospitalet de Llobregat, Spain
- ²⁹ Department of Oncology, Universität Essen, Germany
- ³⁰ National Institute of Oncology, Budapest, Hungary
- ³¹ Oncologist, München, Germany
- ³² Department of Medical Oncology, Institut Catala d'Oncologia, Barcelona, Spain
- ³³ Department of Hemato-Oncology, Hospital, St. Gallen, Switzerland
- ³⁴ Department of Hemato-Oncology, Universität Tübingen, Germany
- ³⁵ Urologist, Hamburg, Germany
- ³⁶ Department of Urology, Universität Köln, Germany
- ³⁷ Department of Urology, Kaiser-Franz-Josef Hospital, Vienna, Austria
- ³⁸ Department of Radiotherapy and Oncology, The Royal Marsden Hospital, Sutton, UK
- ³⁹ Department of Radiotherapy and Oncology, The Royal Marsden Hospital, Sutton, UK
- ⁴⁰ Department of Urology, Princess Margaret Hospital, Toronto, Canada
- ⁴¹ Department of Oncology, Macmillan Consultant in Medical, Leeds, UK
- ⁴² Department of Radiotherapy, Cookridge Hospital, Leeds, UK
- ⁴³ Department of Urology, Ferenc Jahn South-Pest Teaching Hospital, Budapest, Hungary
- ⁴⁴ Department of Oncology, Trondheim University Hospital, Norway
- ⁴⁵ Department of Urology, Universität Münster, Germany
- ⁴⁶ Department of Urology, Theresienkrankenhaus, Mannheim, Germany
- ⁴⁷ Department of Oncology, British Columbia Cancer Agency, Vancouver, Canada
- ⁴⁸ Department of Urology, Med. Hochschule Hannover, Germany
- ⁴⁹ Department of Urology, Academic Medical Center, University of Amsterdam, The Netherlands
- ⁵⁰ Department of Urology, Hospital 12 Octubre, Madrid, Spain
- ⁵¹ Department of Pathology, Vivantes Krankenhaus Am Urban, Berlin, Germany
- ⁵² Department of Oncology, Velindre Hospital, Whitchurch, UK
- ⁵³ Department of Medical Oncology, Southampton General Hospital, UK
- ⁵⁴ Department of Radiooncology, Universität Köln, Germany
- ⁵⁵ Department of Hemato-Oncology, Oregon Health & Science University, USA
- ⁵⁶ Department of Urology, Istituto Nazionale Tumori, Milano, Italy
- ⁵⁷ Department of Oncology, St. Bartholomew's Hospital, London, UK
- ⁵⁸ Department of Oncology, St. Elisabeth Cancer Institute, Bratislava, Slovak Republic
- ⁵⁹ Department of Urology, Academisch Ziekenhuis, Maastricht, The Netherlands
- ⁶⁰ Department of Urology, Hospital 12 de Octubre, Madrid, Spain
- ⁶¹ Department of Urology, Istituto Nazionale Tumori, Milan, Italy
- ⁶² Department of Oncology, Kaiser-Franz-Josef-Hospital, Vienna, Austria
- ⁶³ Urologist, Hamburg, Germany
- ⁶⁴ Department of Oncology, St. Bartholomew's Hospital, London, UK
- ⁶⁵ Department of Hemato-Oncology, REHA-Klinik Reinhardshöhe, Bad Wildungen, Germany
- ⁶⁶ Department of Oncology, Istituto Oncologico Romagnolo, Forli, Italy
- ⁶⁷ Department of Urology, Istituto Nazionale Tumori, Milan, Italy
- ⁶⁸ Department of Radiooncology, Universität Tübingen, Germany
- ⁶⁹ Department of Urology, Krankenhaus Koblenz, Germany
- ⁷⁰ Department of Radiooncology, Universität Mainz, Germany
- ⁷¹ Department of Hemato-Oncology, Martin-Luther-Universität, Halle, Germany

⁷² Department of Urology, Universität Benjamin Franklin, Charité, Berlin, Germany

⁷³ Department of Radiooncology, St. Johannes-Hospital, Salzburg, Austria

⁷⁴ Department of Growth and Reproduction, Rigshospital, Copenhagen, Denmark

⁷⁵ Department of Radiotherapy and Oncology, The Royal Marsden Hospital, Sutton, UK

⁷⁶ Department of Hemato-Oncology, Russian Cancer Res. Centre, Moskov, Russia

⁷⁷ Department of Radiation Oncology, Princess Margaret Hospital, Toronto, Canada

⁷⁸ Department of Urology, Kliniken Essen-Mitte, Huysens-Stiftung, Essen, Germany

⁷⁹ Department of Urology, Euro-Med-Klinik, Fürth, Germany

⁸⁰ Department of Pathology, Universität Leipzig, Germany

⁸¹ Department of Urology, Klinikum Schwerin, Germany

⁸² Department of Medical Oncology, QEII Health Sciences Centre, Halifax, Canada

⁸³ Department of Oncology, Kommunehospital, Arhus, Denmark

Article info

Article history:

Accepted December 6, 2007

Published online ahead of
print on December 26, 2007

Keywords:

Diagnostics in testicular
cancer

Treatment in seminoma CSI

Treatment in non-
seminoma CSI

EU ★ **ACME**

[www.eu-acme.org/
europeanurology](http://www.eu-acme.org/europeanurology)

Please visit

[www.eu-acme.org/
europeanurology](http://www.eu-acme.org/europeanurology) to read and

answer questions on-line.

The EU-ACME credits will
then be attributed
automatically.

Abstract

Objectives: The first consensus report presented by the European Germ Cell Cancer Consensus Group (EGCCCG) in the year 2004 has found widespread approval by many colleagues throughout the world. In November 2006, the group met a second time under the auspices of the Department of Urology of the Amsterdam Medical Center, Amsterdam, The Netherlands.

Methods: Medical oncologists, urological surgeons, radiation oncologists as well as pathologists from several European countries reviewed and discussed the data that had emerged since the 2002 conference, and incorporated the new data into updated and revised guidelines. As for the first meeting, the methodology of evidence-based medicine (EBM) was applied. The results of the discussion were compiled by the writing committee. All participants have agreed to this final update.

Results: The first part of the consensus paper describes the clinical presentation of the primary tumor, its treatment, the importance and treatment of testicular intraepithelial neoplasia (TIN), histological classification, staging and prognostic factors, and treatment of stage I seminoma and non-seminoma.

Conclusions: Whereas the vast majority of the recommendations made in 2004 remain valid 3 yr later, refinements in the treatment of early- and advanced-stage testicular cancer have emerged from clinical trials. Despite technical improvements, expert clinical skills will continue to be one of the major determinants for the prognosis of patients with germ cell cancer. In addition, the particular needs of testicular cancer survivors have been acknowledged.

© 2007 European Association of Urology. Published by Elsevier B.V. All rights reserved.

* Corresponding author. Department of Urology, Krankenhaus Maria Hilf, Oberdießemerstr 94, 47805 Krefeld, Germany. Tel. +49 2151 3342380 81; Fax: +49 2151 3343720. E-mail address: susanne.krege@maria-hilf.de (S. Krege).

1. Diagnosis and staging

In 2004 the first consensus paper on diagnostics and treatment in testicular cancer was prepared by the European Germ Cell Cancer Consensus Group (EGCCCG) [1]. In this interdisciplinary process by medical oncologists, urologic surgeons, radiation oncologists and pathologists the methodology of evidence-based medicine (EBM) was applied

(Table 1) [2,3]. This paper is an update with the new data emerged since 2002 integrated and prepared again on the basis of evidence-based medicine.

1.1. Clinical presentation of germ cell cancer

The majority of patients present with primary tumour in the testis. Delay in diagnosing germ cell

cancer may be caused either by patients who may ignore symptoms too long, or by physicians who fail to make the correct diagnosis: for example, misclassifying a testicular mass as epididymitis or back pain from retroperitoneal disease resulting from vertebral disc problems [EBM III: 4]. Therefore, a high level of suspicion should be maintained in young men with any of these clinical features. In a minority of patients, the primary tumour manifestation is located extragonadally, that is, in the retroperitoneum or the mediastinum. About one third of patients harbour intratubular germ cell neoplasia (ie, testicular intraepithelial neoplasia [TIN]; synonym: carcinoma in situ [CIS]). In another third of patients, ultrasound of the testes reveals scar tissue, indicating a “burned out” testicular tumour that also has to be removed. Therefore, only one third of these patients definitively have a primary extragonadal germ cell tumour [EBM III: 5] (Table 1).

In all young men with a retroperitoneal, supraclavicular, or mediastinal mass, an underlying germ cell cancer should always be considered [EBM III: 4,6,7]. The diagnosis of an extragonadal germ cell tumour is supported by elevated α -fetoprotein (AFP) or human chorionic gonadotropin (β -HCG). In case of unequivocal marker elevation, treatment may start immediately, even without histological confirmation. In case of normal tumour markers, the diagnosis of germ cell cancer must be confirmed by biopsy of the extragonadal mass before treatment is initiated. Histologies of poorly or undifferentiated

carcinoma or poorly differentiated adenocarcinoma should undergo immunohistological evaluation including markers specific for germ cell tumours and, if possible, the expression of isochromosome i(12p), which is also specific for this tumour entity.

1.2. Diagnostic workup for a primary testicular tumour

When assessing the patient’s history, the following risk factors for the development of testicular tumours should be addressed: contralateral testicular tumour [EBM III: 8,9], undescended testis/cryptorchidism [10,11, EBM IIB: 12], poor semen analysis [EBM III: 13–16], and testicular tumour among first-degree relatives, particularly in the father and/or brothers [EBM IIB: 17,18; EBM III: 19].

Mandatory diagnostic examinations (Table 2) include palpation as well as determination of the serum tumour markers AFP, β -HCG, and lactic dehydrogenase (LDH) [EBM IIA: 20–21,22]. If ultrasound of the testes is performed, a >7.5-MHz transducer should be used [22]. Other imaging procedures, that is, magnetic resonance or positron emission tomography of the testis, should not routinely be used, because their results will not alter the clinical management of the patients.

In every case of suspected testicular malignancy, surgical exploration is obligatory. In patients with life-threatening metastatic disease and an unequivocally elevated AFP or β -HCG, orchiectomy should not delay the start of chemotherapy, and may be

Table 1 – Hierarchy of scientific evidence (declining from level IA to IV)

Level	Sources and characteristics of evidence
IA	Evidence obtained from meta-analysis of randomised clinical controlled trials (RCTs) and systematic reviews of RCTs
IB	Evidence obtained from at least one RCT
IIA	Evidence obtained from at least one well-designed controlled study without randomisation
IIB	Evidence obtained from at least one other type of well-designed quasi-experimental study
III	Evidence obtained from well-designed non-experimental descriptive studies, such as comparative studies, correlation studies and case studies
IV	Evidence obtained from expert committee reports or opinions and/or clinical experience of respected authorities without transparent proof

Levels of scientific evidence are based on the definition of the US Agency for Health Care Policy and Research, retrieved through the Cochrane Collaboration [2]: US Department of Human Health Services. Agency for Health Care Policy and Research. Acute pain management: operative or medical procedures and trauma. Rockville (MD): The Agency; 1993. Clinical Practice Guideline No. 1. AHCPR Publication No. 92-0023. p. 107.

Table 2 – Diagnosis and staging of germ cell cancer

Markers, mandatory
Seminoma/non-seminoma \Rightarrow AFP, β -HCG
Metastatic disease \Rightarrow LDH in addition to AFP and β -HCG
Imaging
Testicular ultrasound (7.5-MHz transducer)
Chest X-ray
CT scan of abdomen and pelvis
Chest CT scan (not mandatory for seminoma stage I)
MRT of chest and abdomen: only if contraindication for CT can (eg, contrast media)
MRT (if unavailable: CT) of CNS: in advanced disease or in presence of symptoms
Bone scan: only in presence of symptoms
PET scan:
Identify viable tissue in residual lesion ≥ 3 cm in advanced seminoma if determined ≥ 4 weeks after chemotherapy
Fertility investigations (should be offered):
Total testosterone, LH, FSH, semen analysis, sperm banking

AFP, α -fetoprotein; CT, computed tomography; FSH, follicle-stimulating hormone; HCG, human gonadotropin; LDH, lactate dehydrogenase; LH, luteinising hormone; MRT, magnetic resonance tomography; PET, positron emission tomography.

postponed until later in the treatment course or until the completion of chemotherapy [EBM IB: 23, EBM IIB: 24,25].

2. Treatment of the primary tumour

2.1. Orchiectomy

As a rule orchiectomy is performed before any further treatment (Table 3). Orchiectomy should be scheduled timely (within 1 wk). However, there is no need for emergency (within 24 h) surgery. The results of the tumour marker determination should be available before surgery and have to be reevaluated thereafter to determine the half-life kinetic (half-life time: AFP < 7 d; β -HCG < 3 d).

Radical orchiectomy is performed through an inguinal incision [EBM IIA: 26, EBM IIB: 27,28]. Any scrotal violation for biopsy or open surgery should strongly be avoided. The tumour-bearing testicle is resected along with the spermatic cord at the level of the internal inguinal ring. In patients with negative serum tumour markers and small and possibly benign tumours, histological analysis of a frozen section should be performed before definitive orchiectomy to allow organ-sparing surgery, particularly if a benign tumour is found [EBM IIB: 29,30; EBM III: 31,32].

2.2. Organ-preserving surgery

Organ-preserving surgery might be an alternative to orchiectomy in small primary tumours, but this approach is highly experimental and must be limited to clinical trials. However, in patients with synchronous bilateral tumours, metachronous contralateral tumours, or solitary testicles with normal preoperative testosterone levels, organ-preserving surgery is an alternative procedure to orchiectomy and should be discussed with the patient (Table 3). If

organ-preserving surgery is considered, the patient should always be treated at a center with experience in the management of this rare clinical situation [EBM IIB: 33,34]. If organ-preserving surgery is performed and TIN is histologically documented in the remaining testicular tissue, adjuvant radiotherapy according to the management strategy for TIN in unilateral tumours is recommended [EBM IIB: 33–35]. Adjuvant radiotherapy may be delayed in patients who wish to father children.

3. Diagnosis and treatment of intratubular germ cell neoplasia

3.1. Testicular biopsy in patients with gonadal germ cell cancer

Intratubular germ cell neoplasia (TIN/CIS) is defined as a malignant preinvasive testicular germ cell lesion. In patients with TIN, the cumulative probability for the development of a testicular tumour is 70% after 7 yr [EBM IIB: 36]. Up to 9% of patients with testicular tumours harbour TIN within the contralateral “normal” testicle, which is detectable by open biopsy, best performed as a double biopsy to increase the detection rate to >99% [EBM IIB: 37,38] (Table 4). For patients with testicular volumes < 12 ml and an age < 40 yr, the risk of TIN in the contralateral testis is >34% [EBM IIA: 35,39; EBM IIB: 37,38]. Therefore, the option of a contralateral testicular biopsy should be discussed with the patient, particularly with those at high risk of TIN [EBM IIA: 35]. Contralateral biopsy should be performed preferably at the time of orchiectomy.

Table 3 – Treatment of the primary testis tumor

Radical orchiectomy
Before any further treatment
If life-threatening metastatic disease and unequivocal diagnosis of germ cell tumour by marker elevation: immediate chemotherapy followed by delayed orchiectomy
Organ-preserving surgery of testis tumour may be considered in case of
Synchronous bilateral testis tumours
Metachronous contralateral (second) testis tumour
Tumour in a solitary testis and sufficient endocrine function
Performed at experienced centres only!

Table 4 – Prevalence and diagnosis of TIN in the testis not affected by germ cell tumour

Biopsy for detection of TIN in contralateral testis
9% of all patients with testicular tumour
≥34% TIN in patients with testicular atrophic volume <12 ml and age <40 yr
≥33% TIN in patients with extragonadal germ cell tumour before chemotherapy
Approximately 10% TIN in patients with extragonadal germ cell tumour after chemotherapy
If untreated, invasive testis tumour develops in 70% of TIN-positive testis within 7 yr;
99% of TIN detected by biopsy
Biopsy not mandatory but strongly recommended in
High-risk patients (atrophy and young age)
Extragenadal germ cell tumour (before chemotherapy, if not prior, then not earlier than 2 yr after chemotherapy)
Contralateral testis, one or both testes in extragonadal germ cell tumour
TIN, intratubular germ cell neoplasia.

Biopsies to identify TIN are best preserved in Stieve's or Bouin's solution (not in formalin!) [EBM IIB: 40,41].

3.2. Testicular biopsy in patients with extragonadal germ cell cancer

About one third of patients with extragonadal germ cell cancer harbour TIN within one or both testicles, which otherwise appear normal. The cumulative risk of developing a metachronous testicular cancer 10 yr after diagnosis and treatment of extragonadal germ cell tumours is only 10%; the risk is higher among patients with non-seminomatous histology or retroperitoneal location than among patients with pure seminomatous histology (1.4%) or primary mediastinal location (6.2%) [EBM III: 6]. However, because all patients with extragonadal germ cell cancer will receive platin-based chemotherapy, which will eliminate a substantial percentage of TIN, a routinely performed bilateral testicular biopsy is not recommended (Table 4). Nevertheless, if biopsy is planned in patients with a higher risk for TIN after an extragonadal germ cell tumour, the biopsy should be preferably performed before chemotherapy [22, EBM III: 42,43]. If performed thereafter, testicular biopsy should be considered not earlier than 2 yr after the completion of chemotherapy [22, EBM III: 42,43].

3.3. Treatment of TIN

3.3.1. TIN in the contralateral testis or in the affected single testis after organ-preserving surgery

There are three possible options in this clinical situation, that is, orchiectomy, radiotherapy, or a surveillance strategy (Table 5); all options should be discussed with the patient. Both orchiectomy and radiotherapy offer definitive treatment of TIN, but

will destroy potential residual fertility. Because the interval between diagnosis of TIN and the development of a testicular tumour is usually long, a surveillance strategy is justified for patients who want to father children and have residual spermatogenesis sufficient at least for assisted fertilization. In the case of surveillance strategy, regularly performed evaluation of the TIN-bearing testicle by ultrasound is mandatory.

If radiation treatment is chosen, a total dose of 20 Gy (single doses of 2 Gy, five fractions per week) seems to be the most appropriate treatment to eliminate all TIN loci [EBM III: 44–47]. For preservation of testosterone production, radiation doses <20 Gy have been investigated. Whereas the potential benefit of this strategy is uncertain, a radiation dose <20 Gy may result in lower frequencies of complete TIN eradication [EBM IIB: 48–50]. After radiation treatment, regular determination of the serum testosterone levels should be performed, because radiation may impair Leydig cell function [EBM IIB: 49]. The same evaluation applies to patients after organ-preserving surgery. All patients with subnormal testosterone levels and clinical signs of androgen deficiency should be offered hormone supplementation treatment.

3.3.2. Treatment of TIN in patients without overt gonadal tumours

TIN may be found incidentally in a testis investigated for other reasons (infertility or extragonadal germ cell tumours). In patients with a normal contralateral testicle, orchiectomy is a reasonable choice for definitive treatment, because radiation treatment of TIN might impair fertility of the contralateral unaffected testicle owing to scattered radiation (Table 5). This particularly applies to patients with an atrophic TIN-bearing testicle.

3.3.3. Treatment of TIN in patients scheduled to receive chemotherapy

If chemotherapy is planned in patients with TIN, radiation treatment should be postponed to avoid extensive damage to Leydig cells by the combination of chemotherapy and irradiation (Table 5). Furthermore, in about two thirds of patients, TIN will be eradicated by chemotherapy alone [EBM IIB: 48; EBM III: 46,51]. Biopsies performed early after chemotherapy might not detect TIN. Therefore, a further biopsy may be considered in those patients not earlier than 2 yr after chemotherapy has been completed. Technically, biopsies at two sites are strongly recommended in this particular situation, because TIN cells will probably be low in number secondary to chemotherapy; thus, a single random biopsy

Table 5 – Treatment of testicular intraepithelial neoplasia

TIN in contralateral testis or in case of organ-preserving surgery
If fertility should be maintained ⇒ delay definitive treatment by active surveillance until conception, followed by active treatment or further surveillance
If fertility not relevant ⇒ irradiation 20 Gy (2 Gy, 5×/wk)
TIN in patients without gonadal tumour (incidental diagnosis, eg, by biopsy for infertility or extragonadal germ cell tumour)
Orchiectomy to be preferred over irradiation (potential damage of contralateral not affected testis by scattered radiation)
TIN in patients receiving chemotherapy (either as adjuvant treatment or for advanced or extragonadal disease)
Because chemotherapy eradicates TIN in 2/3 of the patients with TIN before chemotherapy, definitive treatment for TIN only if TIN is diagnosed at (re)biopsy after chemotherapy
TIN, testicular intraepithelial neoplasia.

would have a high probability of missing the diagnosis [EBM IIB: 37,38]. In cases of TIN persisting after chemotherapy, those patients should be managed as described above.

4. Histological examination of germ cell cancer

It is recommended to completely laminate the testicular specimen in transverse sections. Additional sections have to be taken from the spermatic cord. For full histological examination of the tumour, it is necessary to obtain one block per centimetre of tumour, not less than a total of three blocks, as well as blocks from the peritumoural region and of remote testicular tissue. Further samples have to be taken from the funicular resection margin and from the spermatic cord within a 1-cm distance to the testicle. Immunohistology can include staining for cytokeratin for the detection of non-seminomatous elements, CD31/factor VIII for the identification of vessel endothelium; however, AFP and β -HCG are mandatory. TIN may be identified with the use of hematoxylin-eosin preparations or placental alkaline phosphatase staining, or by semithin-section technique.

There are two types of seminoma: seminoma with a subtype “seminoma with syncytiotrophoblastic cells” and spermatocytic seminoma with a subtype “spermatocytic seminoma with sarcoma.” The World Health Organization (WHO) classification (Table 6) [52] mentions only teratoma without subdivision into mature and immature forms. Poly-embryoma is no longer listed. The histopathological report must address the following issues (Table 7): localisation and size of the tumour, multiplicity, tumour extension (rete testis, tunica albuginea, tunica vaginalis, epididymis, spermatic cord, scrotum), pT category according to the International Union Against Cancer (UICC) classification [53], histological type (WHO-ICD-O-M), the presence or absence of TIN, and the presence or absence of vascular invasion of blood or lymphatic vessels [54]. In tumours with pluriform structures, each individual component and its estimated relative proportion must be documented. Similarly, evidence of syncytiotrophoblasts should be indicated in seminoma as well as any additional sarcomatous elements in spermatocytic seminomas as recommended by the WHO. Because of the clinical importance, it is highly recommended that all histological specimens be assessed by a pathologist experienced in testis cancer pathology [55].

Table 6 – WHO classification of germ cell tumours of the testis [51]

Histological type [53]	ICD-O-M
Intratubular germ cell neoplasia, unclassified	9064/2
Others	
Tumours of one histological type (pure forms)	
Seminoma	9061/3
(Subtype) Seminoma with syncytiotrophoblastic cells	
Spermatocytic seminoma	9063/3
(Subtype) Spermatocytic seminoma with sarcoma	
Embryonal carcinoma	9070/3
Yolk sac tumour	9071/3
Trophoblastic tumours	
Choriocarcinoma	9100/3
Trophoblastic neoplasms other than choriocarcinoma	
Monophasic choriocarcinoma	
Placental site trophoblastic tumour	9104/1
Teratoma	9080/3
Dermoid cyst	9084/0
Monodermal teratoma	
Teratoma with somatic type malignancies	9084/3
Tumours of more than one histological type (mixed forms)	
Mixed embryonal carcinoma and teratoma	9081/3
Mixed teratoma and seminoma	9085/3
Choriocarcinoma and teratoma/embryonal carcinoma	9101/3
Others	

WHO, World Health Organization.

4.1. Staging procedures and prognostic classification

Defining the clinical stage (CS) of a patient with a gonadal germ cell tumour is based on the UICC TNM classification (Table 8) [53]. For verification of CS I disease, markers should be followed after orchiectomy until normalization is achieved. Patients without marker normalization after orchiectomy are defined as stage I S disease. Patients with metastatic disease are classified according to the

Table 7 – Histopathological report of testicular tumour

Localisation
Size
Multiplicity
Extension of tumour (eg, rete testis involvement etc.)
pT category (UICC)
Histopathological type (WHO)
In seminoma: presence of syncytiotrophoblasts
In pluriform tumours: description of each individual component
Presence of vascular invasion
Presence of TIN

TIN, testicular intraepithelial neoplasia; UICC, International Union Against Cancer; WHO, World Health Organization.

Table 8 – TNM classification (UICC 2002) [53]

pT	Primary tumour
pTX	Primary tumour cannot be assessed
pT0	No evidence of primary tumour (eg, histological scar in testis)
pTis	Intratubular germ cell neoplasia (carcinoma in situ)
pT1	Tumour limited to testis and epididymis without vascular/lymphatic invasion: tumour may invade tunica albuginea but not tunica vaginalis
pT2	Tumour limited to testis and epididymis with vascular/lymphatic invasion, or tumour extending through tunica albuginea with involvement of tunica vaginalis
pT3	Tumour invades spermatic cord with or without vascular/lymphatic invasion
pT4	Tumour invades scrotum with or without vascular/lymphatic invasion
N	Regional lymph nodes clinical
NX	Regional lymph nodes cannot be assessed
N0	No regional lymph node metastasis
N1	Metastasis with a lymph node mass 2 cm or less in greatest dimension or multiple lymph nodes, none more than 2 cm in greatest dimension
N2	Metastasis with a lymph node mass more than 2 cm but not more than 5 cm in greatest dimension, or multiple lymph nodes, any one mass more than 2 cm but not more than 5 cm in greatest dimension
N3	Metastasis with a lymph node mass more than 5 cm in greatest dimension
pN	Pathological
pNX	Regional lymph nodes cannot be assessed
pN0	No regional lymph node metastasis
pN1	Metastasis with a lymph node mass 2 cm or less in greatest dimension and 5 or fewer positive nodes, none more than 2 cm in greatest dimension
pN2	Metastasis with a lymph node mass more than 2 cm but not more than 5 cm in greatest dimension; or more than 5 nodes positive, none more than 5 cm; or evidence of extranodal extension of tumour
pN3	Metastasis with a lymph node mass more than 5 cm in greatest dimension
M	Distant metastasis
MX	Distant metastasis cannot be assessed
M0	No distant metastasis
M1	Distant metastasis
M1a	Non-regional lymph nodes(s) or lung
M1b	Other sites
S	Serum tumour markers
Sx	Serum marker studies not available or not performed
S0	Serum marker study levels within normal limits LDH (U/l) HCG (mIU/ml) AFP (ng/ml)
S1	<1.5 × N and <5000 and <1000
S2	1.5–10 × N or 5000–50,000 or 1000–10,000
S3	>10 × N or >50,000 or >10,000

N indicates the upper limit of normal for the LDH assay.
 Except for pTis and pT4, where radical orchiectomy is not always necessary for classification purposes, the extent of the primary tumour is classified after radical orchiectomy; see pT in other circumstances. TX is used if no radical orchiectomy has been performed.
 According to the 2002 TNM classification, stage I testicular cancer includes the following substages:

Stage IA	pT1	NO	MO	S0
Stage IB	pT2, pT3, or pT4	NO	MO	S0
Stage IS	Any pT/TX	NO	MO	S1–3

AFP, α-fetoprotein; HCG, human gonadotropin; LDH, lactate dehydrogenase UICC, International Union Against Cancer.

classification of the International Germ Cell Cancer Collaborative Group (IGCCCG) [56], which includes histology, location of primary tumour, location of metastases, and levels of AFP, β-HCG, and LDH after orchiectomy and before chemotherapy, as prognostic markers to categorise patients into “good,” “intermediate,” and “poor” prognosis groups (Table 9). The individual treatment strategy is based on both the TNM classification and the IGCCCG classification based on prognostic factors.

4.2. Prognostic factors in low-volume disease

4.2.1. Seminoma CS I

Although no prognostic classification system has been prospectively validated, there is evidence from surveillance studies that the size of the primary tumour (≤ 4 cm vs. >4 cm) and infiltration of the rete testis are independent prognostic indicators for occult metastases [EBM IIB: 57]. Patients with both factors represent a high-risk

Table 9 – IGCCCG prognostic grouping classification [56]

Prognosis	5-year survival	Non-seminoma	Seminoma
Good	90%	<ul style="list-style-type: none"> • Testis or primary extragonadal retroperitoneal tumour • and no non-pulmonary visceral metastases • and low markers • AFP < 1000 ng/ml, • and β-HCG < 1000 ng/ml (<5000 IU/l) • and LDH < 1.5\times normal level 	<ul style="list-style-type: none"> • Any primary localisation • and no non-pulmonary visceral metastases • Any marker level
Intermediate	75%	<ul style="list-style-type: none"> • Testis or primary extragonadal retroperitoneal tumour • and no presence of <ul style="list-style-type: none"> • non-pulmonary visceral metastases • and intermediate markers • AFP 1000–10,000 ng/ml • and/or β-HCG 1000–10,000 ng/ml • (5000–50,000 IU/l) • and/or LDH 1.5–10\times normal level 	<ul style="list-style-type: none"> • Any primary localisation • and presence of non-pulmonary visceral metastases (liver, CNS, bone, intestine) • Any marker level
Poor	50%	<ul style="list-style-type: none"> • Primary mediastinal germ cell tumour with or without testis or • primary retroperitoneal tumour • and presence of non-pulmonary visceral metastases (liver, CNS, bone, intestine) • and/or “high markers” • AFP >10,000 ng/ml • and/or β-HCG > 10,000 ng/ml (50,000 IU/l) • and/ or LDH > 10\times normal level 	—

AFP, α -fetoprotein; β -HCG, human chorionic gonadotropin; CNS, central nervous system; IGCCCG, International Germ Cell Cancer Collaborative Group; LDH, lactic dehydrogenase.

population, with a recurrence rate as high as 32%. These histopathological parameters should therefore be documented. Patient age (<34 vs. \geq 34 yr) and the presence of vascular invasion (VI) are of equivocal prognostic relevance [EBM IIA: 58,59; EBM IIB: 57; EBM III: 59,60].

4.2.2. Non-seminoma CS I

Infiltration of venous blood vessels or lymphatic infiltration (ie, VI) by the primary tumour are the most important prognostic indicators for occult metastases, and must be assessed in all patients [EBM IB: 61, EBM IIA: 62–65, EBM IIB: 66–71, EBM III: 72–76]. Without adjuvant treatment, 48% of the patients with VI will develop metastases, whereas only 14–22% of those without this treatment will relapse [EBM IIB: 67]. The proliferation rate and the percentage of embryonal carcinoma in relation to the total tumour volume are further prognostic indicators [EBM IIB: 64,67,68,71; EBM III: 72–78]. However, these markers do not contribute

independent prognostic information in addition to the factor of VI.

4.2.3. Non-seminoma pathological stage (PS) IIA/B

If no adjuvant chemotherapy after retroperitoneal lymph node dissection is administered [EBM III: 79], the volume of the retroperitoneal mass (<2 cm [PS IIA] vs. 2–5 cm [PS IIB]) and the presence of VI within the primary tumour are independent prognostic indicators for relapse.

4.2.4. Imaging procedures

Recommendations concerning staging investigation are frequently based on low-level evidence rather than on the results of prospective phase 3 studies. Therefore, meaningful EBM graduation frequently cannot be given [80].

Computed tomography (CT) of the chest, abdomen, and pelvis are required as initial staging investigations. CT of the chest may be omitted for patients with testicular seminoma presenting

without a retroperitoneal tumour mass. Oral and intravenous contrast media are mandatory [70,81–85]. For evaluation of the lung and mediastinum, chest CT scan is more sensitive than plain X-ray films [70,85–87]. However, it should be noted that pulmonary/pleural nodules of <1 cm can represent a false-positive finding in CT scans [82,EBM IIB: 70,85; EBM III: 75,86,88]. Furthermore, CT scans of the abdomen and pelvis might give false-negative results in up to 30% of cases, because of difficulties in the interpretation of lymph nodes based on morphology and size alone. Therefore, the differentiation between clinical stages I and IIA is unreliable, if both AFP and β -HCG are normal [82–84,89,90]. A detailed description of the location, number, and size of lymph nodes should be provided in the radiology report. Ultrasound of the retroperitoneum is less sensitive than CT [84]. Magnetic resonance tomography scans of the abdomen and pelvis do not provide additional information and should be restricted to patients to whom intravenous contrast media cannot be given [91,92]. On the basis of available data, PET has not conclusively demonstrated to improve sensitivity of staging compared with CT scanning alone. Not even in high-risk stage I patients was PET sensitive enough to predict early metastatic disease in a statistically significant proportion of patients [EBM IIB: 93,94]. PET scans are not recommended outside clinical trials as part of routine initial staging procedures [95–101]. Bone scans should be obtained in patients in whom bone metastases are clinically suspected. Imaging of the brain, preferably by magnetic resonance tomography, is required in patients with clinical symptoms and signs indicating brain metastases, particularly when they occur in patients with advanced disease [EBM III: 102,103].

5. Treatment-associated fertility issues and sperm banking

In patients of reproductive age, baseline fertility assessment should be performed, including the determination of total testosterone level, luteinising hormone, follicle-stimulating hormone, and semen analysis. The patient must be informed about and offered the possibility of cryoconservation, preferably carried out before orchiectomy [EBM IIB: 50; EBM III: 47,104,105; EBM IV: 106–108]. Patients with bilateral testicular tumours, or a testicular tumour with contralateral TIN and with severe oligo-, azo-, or aspermia should be informed about the option of testicular sperm extraction [EBM III: 44, EBM III/IV: 108–112].

5.1. Testosterone replacement

In patients with bilateral orchiectomy, lifelong testosterone replacement must be offered to maintain sexual functioning and avoid late toxicity from hypogonadism. After unilateral orchiectomy, the necessity for testosterone supplementation depends on testosterone serum levels and clinical symptoms [113].

5.2. Contraception

Although no increased risk of malformation in children born after the end of cytotoxic treatment has been reported, contraception throughout chemo- or radiotherapy as well as for 1 yr of follow-up is suggested [EBM III: 114].

6. Treatment of patients with seminoma CS I

Despite normal CT scans, up to 32% of patients with CS I seminoma can relapse if no adjuvant treatment is given [EBM IIB: 57,115,116]. Nevertheless, the cure rate in CS I seminoma patients is almost 100% and can be achieved with three strategies: surveillance with salvage irradiation or chemotherapy at relapse, adjuvant chemotherapy with single-agent carboplatin, and—with the most mature follow-up data—adjuvant radiation treatment [EBM IB: 117; EBM IIB: 118–120]. Tumour size >4 cm and rete testis invasion have been recognized as risk factors for occult metastatic disease in retrospective analyses [EBM IIB: 57]. Patients with both risk factors represent a high-risk group with a relapse rate that may be as high as 32%. These risk factors can be used to advise patients in making their treatment selection. With the use of the risk-adapted strategy, low-risk patients may be managed by surveillance as the preferred treatment option, if compliance and follow-up can be ascertained. High-risk patients can be treated with surveillance or adjuvant treatment on the basis of a patient's preference. All three treatment options, surveillance, adjuvant carboplatin, or adjuvant radiotherapy are acceptable strategies for the management of patients with CS I seminoma (Fig. 1).

The risks and benefits of any of the three strategies—for example, the potential of relapse using surveillance (Fig. 1) and the potential for late toxic effects from adjuvant treatment—have to be discussed with the patient, taking into account not only the individual preferences of the patient, but also the experience with each strategy at the local treatment centre.

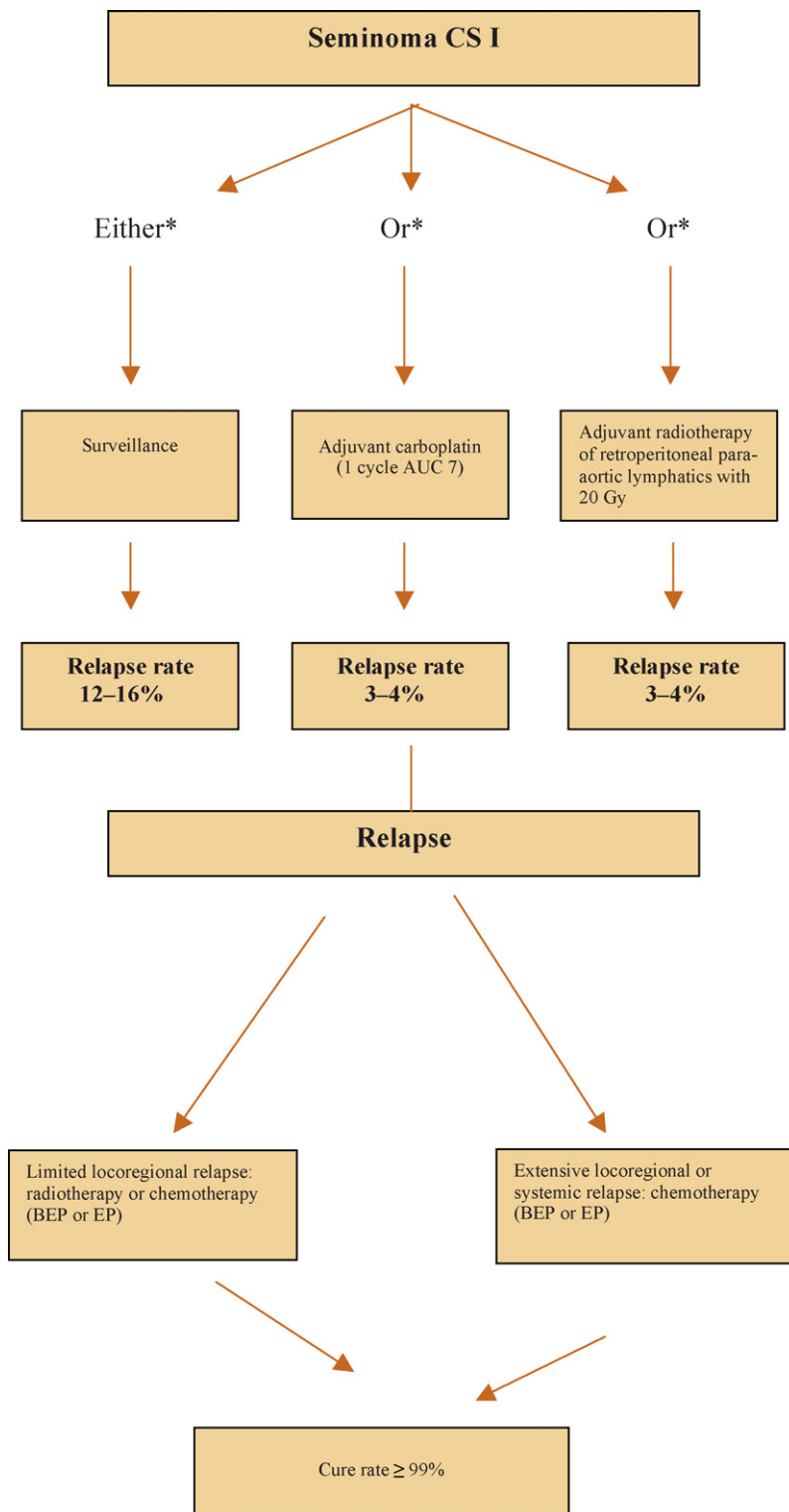


Fig. 1 – Treatment algorithm after orchiectomy according to individual risk factors in patients with seminoma clinical stage (CS) I. * A risk-adapted approach to the treatment of seminoma stage I patients may be chosen. AUC, area under the curve; BEP, bleomycin, etoposide, cisplatin; EP, etoposide, cisplatin.

6.1. Surveillance

A surveillance strategy should be used as the preferred treatment option in patients in whom

this approach is considered feasible [EBM IIB: 115,116]. This recommendation takes into account that up to 88% of patients can be cured by orchiectomy and are therefore overtreated by any

adjuvant treatment. The results of a retrospective meta-analysis of patients managed by surveillance indicate a 5-yr relapse rate of 12% without any risk factor, a 16% risk of relapse at 5 yr in case of one risk factor, and a 32% relapse rate in case of two risk factors (tumour size > 4 cm; tumour invasion of the rete testis) [EBM IIB: 57]. The second Spanish Germ Cell Cancer Cooperative Group study about the efficacy of a risk-adapted treatment policy using the same risk factors even showed a 5-yr disease-free survival rate of 93.4% in patients without any of these risk factors, who therefore were treated by surveillance [EBM IIB: 121]. Relapses will occur in 97% of cases in the retroperitoneal or high iliac lymph nodes [EBM IIB: 58,116,122,123] and may occur as late as 10 or more years after orchiectomy [EBM IIB: 58,116,124, EBM III: 125]. This higher risk of relapse requires prolonged follow-up of patients. Treatment of those patients who relapse is usually more intensive [EBM IIB: 115, EBM III: 125]. Because of the higher risk of relapse, patients managed by surveillance may experience greater psychological stress than those receiving adjuvant treatment [EBM III: 126].

6.2. Adjuvant carboplatin

One alternative to surveillance is adjuvant chemotherapy with one cycle of carboplatin area under the curve (AUC) 7. The analysis of the large Medical Research Council/European Organization for Research and Treatment of Cancer (MRC/EORTC) trial, which compared adjuvant treatment with either radiation or one-cycle single-agent carboplatin AUC 7, revealed no significant difference in relapse rate, time to relapse, and survival after a median of 4-yr follow-up [EBM IB: 117]. The patterns of relapse differed [EBM IB: 117; EBM IIB: 118–120] (more retroperitoneal lymph node relapse with carboplatin vs. more pelvic lymph node relapse with adjuvant irradiation), but the ease of carboplatin administration, the shorter time to deliver adjuvant treatment, and the reduction of contralateral testis tumours (2 of 573 vs. 10 of 904 patients) could offer a clinical advantage of carboplatin over adjuvant radiotherapy.

6.3. Adjuvant radiotherapy

Another alternative to surveillance is adjuvant radiotherapy, resulting in a relapse rate of 3–4%. Almost all of these recurrences are located outside the irradiated area, mostly in the pelvis (1.7%) or close to the border of the radiation fields [EBM IB: 127,128, EBM IIA: 129,130]. The target volume of

irradiation includes the infradiaphragmatic para-aortal/paracaval lymphatics [EBM IB: 127,128, EBM IIA: 129,130]. The upper and lower field margins are defined by the upper edge of the thoracic vertebra 11 and the lower edge of the lumbar vertebra 5. Ipsilateral to the primary tumour, the lateral field margin should be extended to the renal hilum; the contralateral margin has to include the processus transversus of the lumbar vertebrae. The total dose is 20 Gy, applied in single doses of 2.0 Gy each, five fractions per week, based on the results of the prospective randomized trial of the MRC, which compared 30 Gy with 20 Gy [EBM IB: 128]. The use of a linear accelerator is mandatory. An extension of the irradiation field to the ipsilateral iliacal, inguinal, or scrotal region in the event of prior testicular maldescensus, inguinal, or scrotal violations or pT3–4 primary tumours is probably not indicated, because there is no evidence for a different treatment outcome [EBM IIA: 26, EBM III: 131–132].

Limited target volume and doses of modern adjuvant radiotherapy have substantially reduced treatment-related side-effects, such as impairment of fertility owing to scatter radiation doses to the remaining testicle [EBM IB: 127; EBM IIB: 133]. Nevertheless, shielding of the contralateral testis is recommended [EBM IIA: 134]. Adjuvant radiation therapy may be associated with mild, acute side-effects (usually WHO grade I–II), predominantly in the form of gastrointestinal symptoms [EBM IIA: 130]. Relapse after radiation is nearly always located outside the radiation field [EBM IIB: 118, EBM IIA: 130, EBM IIB: 135,136]. Compared with no adjuvant treatment, there is a small risk of secondary malignancies after radiation therapy [EBM III: 137–139]. However, data are not yet available that quantify the risks of secondary malignancies when modern radiation techniques are applied with reduced doses and limited target volumes.

6.4. Summary of treatment of seminoma CS I

Taken together, all three treatment options for seminoma CS I result in a different relapse rate (3–4% for irradiation or adjuvant carboplatin vs. 13–20% for surveillance), but there is a final cure rate of nearly 100% if the first-line treatment approach and follow-up are applied properly.

7. Treatment of patients with non-seminoma CS I

If treatment is performed correctly, the cure rate of patients with non-seminoma CS I should be 99%,

regardless of the management chosen [EBM IIB: 67,140]. In the case of surveillance, the relapse rate is 27–30% when considering a long-term follow up of ≤ 20 yr [EBM IIB: 71,140]. Relapses occur in the retroperitoneum in 54–78% of patients, and in the lung in 13–31%, but are very rarely found in more than one visceral organ [EBM IB: 141, EBM IIB: 140, EBM III: 142].

VI of the primary tumour is the most important prognostic indicator for relapse. Patients with VI have a 48% risk of developing metastatic disease

[EBM IB: 61, EBM IIB: 67], whereas only 14–22% of patients without VI will relapse [EBM IB: 61, EBM IIA: 63, EBM IIB: 64,71]. A risk-adapted strategy based on the presence or absence of VI is the recommended standard procedure [EBM IIB: 143] (Fig. 2).

Patients with a low risk of relapse (ie, no VI) should be managed by surveillance according to the MRC recommendations for follow-up, which require at least three CT scans performed at 0, 3, and 12 mo [EBM IB: 144]. With this approach 78–86% of patients do not need any further treatment after orchiectomy

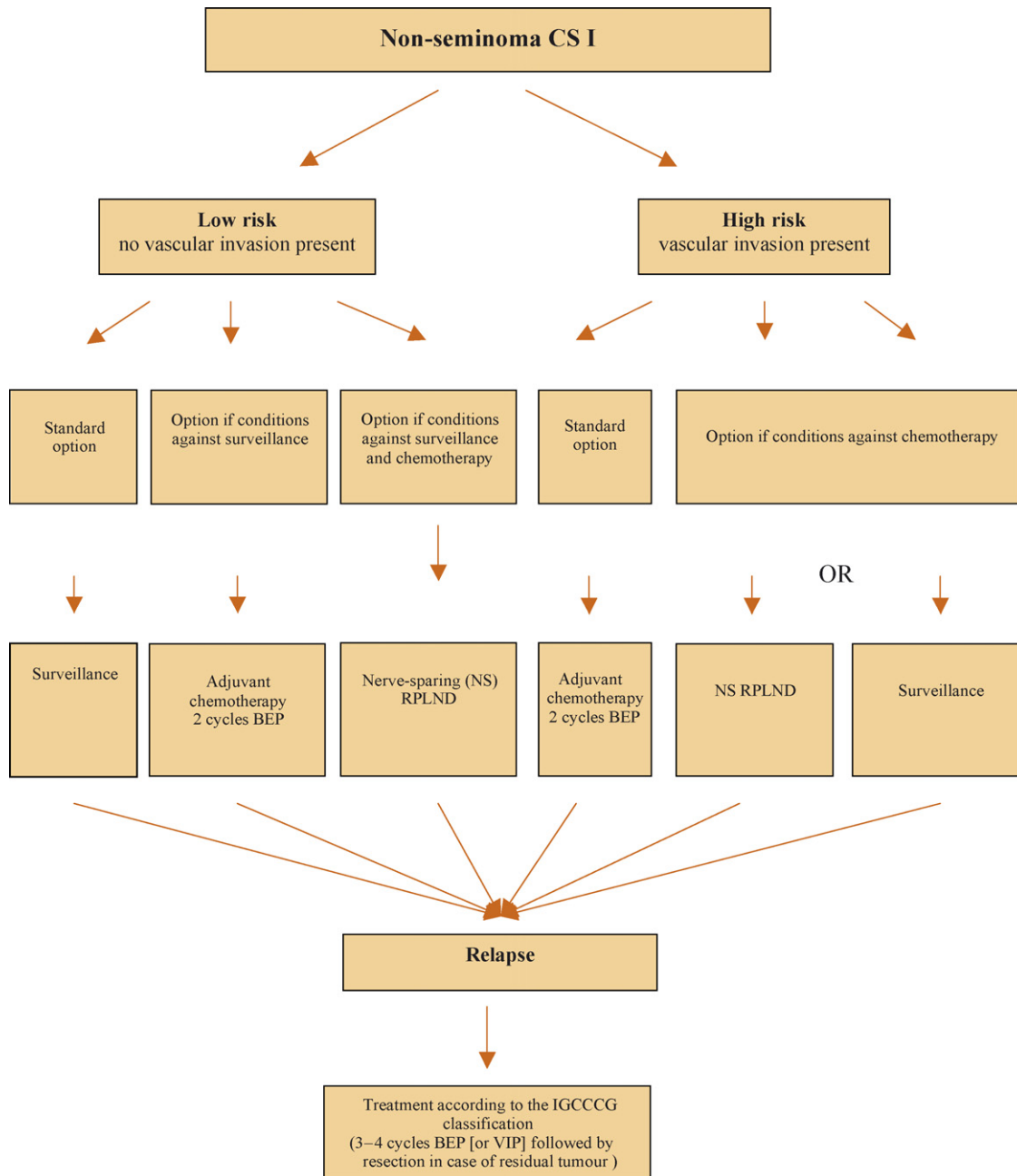


Fig. 2 – Treatment algorithm after orchiectomy according to individual risk factors in patients with non-seminoma clinical stage I. BEP, bleomycin, etoposide, cisplatin; CS, clinical stage; IGCCCG, International Germ Cell Cancer Collaborative Group; RLND, retroperitoneal lymph node dissection; VIP, vasoactive intestinal peptide.

[EBM IIA: 63; EBM IIB: 64,71]. If a patient under surveillance relapses, the administration of chemotherapy will result in a cure rate close to 100%. Only in circumstances not suitable for surveillance is adjuvant chemotherapy with two cycles of bleomycin, etoposide, and cisplatin (BEP) recommended. Nerve-sparing retroperitoneal lymph node dissection (RPLND) is an option at high-volume expert centers [EBM III: 145]. However, a randomized phase 3 trial of one-cycle BEP versus RPLND in 382 unstratified patients with CSI disease (plus adjuvant chemotherapy for those who would be pathological stage II after RPLND) suggested a significantly reduced recurrence rate using adjuvant BEP compared with surgery (1.1% vs. 7.5%, respectively) [EBM IB: 146]. These results have to be verified in a randomized phase 3 trial comparing one versus two cycles of BEP in high-risk patients with non-seminoma CSI. Such a study has been initiated by the German Testicular Cancer Study Group.

Patients with a high risk of relapse (ie, presence of VI) should receive adjuvant chemotherapy with two cycles of BEP. In special indications surveillance or RPLND is a possible alternative strategy to adjuvant chemotherapy, if proper conditions exist. By this approach 97% of patients will remain relapse-free, and the overall cure rate is >99% [EBM IIB: 67,147].

The disadvantage of adjuvant treatment in high-risk patients is that half of the patients who receive adjuvant BEP would not have required chemotherapy at all and may be unnecessarily exposed to the side-effects of chemotherapy [EBM IB: 148, EBM IIA: 149, EBM III: 150–155], a possible transient decrease in fertility [EBM III: 104,156–158], and possibly a small risk of secondary malignancies, as reported from patients receiving higher doses of chemotherapy [EBM III: 137–139,159]. However, surveillance in high-risk patients with a relapse rate of 48% exposes patients to psychological distress [EBM III: 126]. Relapses might be detected later, and subsequent treatment is more intensive compared with immediate adjuvant treatment. Nevertheless, if surveillance is carried out properly, >98% of these patients will still have a good prognosis and are cured by chemotherapy at the time of relapse. The negative predictive value of relapse can be predicted with 87% certainty if the proliferation rate of <70% and the percentage of VI < 50% are considered in addition to VI [EBM IB: 61].

In patients unwilling to undergo a surveillance strategy or adjuvant chemotherapy, a nerve-sparing lymphadenectomy (NS-RPLND) may be performed [EBM IIA: 160, EBM III: 161,162]. However, patients who choose NS-RPLND will be unnecessarily exposed to surgery in 50% of cases with the risk of

surgery-associated side-effects [EBM IIB: 140], particularly, a 6–8% risk of retrograde ejaculation [EBM IIB: 140, EBM III: 163,164]. In addition, NS-RPLND does not completely eliminate the risk of recurrence, and relapses will occur in ~10% of cases, with almost all of these relapses outside of the retroperitoneum being located in the lungs. Late relapses are rare [EBM III: 125].

Conflicts of interest

The authors have nothing to disclose.

Acknowledgements

This consensus document was made possible by the input of the participants of the 2006 consensus conference who discussed and prepared this update of the 2002 consensus meeting.

All participants particularly like to thank Dr M. Pilar Laguna, Mrs Sonja van Rees Vellinga, and Karin Plass for organizing the meeting.

References

- [1] Schmoll H-J, Souchon R, Krege S, et al. European consensus on diagnosis and treatment of germ cell cancer: a report of the European Germ Cell Cancer Consensus Group (EGCCCG). *Ann Oncol* 2004;15:1377–99.
- [2] US Department of Human Health Services. Acute pain management: operative or medical procedures and trauma. Clinical Practice Guideline No. 1. AHCPR Publication No. 92-0023. Rockville, MD: Agency for Health Care Policy and Research 1993. p. 107.
- [3] Woolf SH. Practice guidelines, a new reality in medicine II. Methods of developing guidelines. *Arch Intern Med* 1992;152:946–52.
- [4] Bokemeyer C, Droz JP, Horwich A, et al. Extragonadal seminoma: an international multicenter analysis of prognostic factors and long term treatment outcome. *Cancer* 2001;91:1394–401 (EBM III).
- [5] Scholz M, Zehender M, Thalmann GN, et al. Extragonadal retroperitoneal germ cell tumor: evidence of origin in the testis. *Ann Oncol* 2002;13:121–4 (EBM III).
- [6] Hartmann JT, Fossa SD, Nichols CR, et al. Incidence of metachronous testicular cancer in patients with extragonadal germ cell tumors. *J Natl Cancer Inst* 2001;93:1733–8 (EBM III).
- [7] Hartmann JT, Nichols CR, Droz JP, et al. Prognostic variables for response and outcome in patients with extragonadal germ-cell tumors. *Ann Oncol* 2002;13:1017–28 (EBM III).
- [8] Geczi L, Gomez F, Bak M, et al. The incidence, prognosis, clinical and histological characteristics, treatment and

- outcome of patients with bilateral germ cell testicular cancer in Hungary. *J Cancer Res Clin Oncol* 2003;129:309–15 (EBM III).
- [9] Hentrich M, Weber N, Bergsdorf T, et al. Management and outcome of bilateral testicular germ cell tumors: twenty-five year experience in Munich. *Acta Oncol* 2005;44:529–36 (EBM III).
- [10] Dieckmann KP, Pichlmeier U. Clinical epidemiology of testicular germ cell tumors. *World J Urol* 2004;22:2–14.
- [11] Garner MJ, Turner MC, Ghardirian P, et al. Epidemiology of testicular cancer: an overview. *Int J Cancer* 2005;116:331–9.
- [12] Pinczowski D, McLaughlin JK, Lackgren G, et al. Occurrence of testicular cancer in patients operated on for cryptorchidism and inguinal hernia. *J Urol* 1991;146:1291–4 (EBM IIB).
- [13] Jacobsen R, Bostofte E, Engholm G, et al. Risk of testicular cancer in men with abnormal semen characteristics: cohort study. *BMJ* 2000;321:789–92 (EBM III).
- [14] Hoei-Hansen CE, Holm M, Rajpert-De Meyts E, Skakkebaek NE. Histological evidence of testicular dysgenesis in contralateral biopsies from 218 patients with testicular germ cell cancer. *J Pathol* 2003;200:370–4 (EBM III).
- [15] Doria-Rose VP, Biggs ML, Weiss NS. Subfertility and the risk of testicular germ cell tumors (United States). *Cancer Causes Control* 2005;16:651–6 (EBM III).
- [16] Raman JD, Nobert CF, Goldstein M. Increased incidence of testicular cancer in men presenting with infertility and abnormal semen analysis. *J Urol* 2005;174:1819–22 (EBM III).
- [17] Westergaard T, Olsen JH, Frisch M, et al. Cancer risk in fathers and brothers of testicular cancer patients in Denmark. A population based study. *Int J Cancer* 1996;66:627–31 (EBM IIB).
- [18] Dieckmann KP, Pichlmeier U. The prevalence of familial testicular cancer. *Cancer* 1997;80:1954–60 (EBM IIB).
- [19] Hemminki K, Li X. Familiar risk in testicular cancer as a clue to a heritable and environmental aetiology. *Br J Cancer* 2004;90:1765–70 (EBM III).
- [20] de Takats PG, Jones SR, Penn R, et al. a-Fetoprotein heterogeneity: what is its value in managing patients with germ cell tumours? *Clin Oncol (R Coll Radiol)* 1996;8:323–6 (EBM IIA).
- [21] Hartmann M, Pottek T, Bussar-Maatz R, et al. Elevated human chorionic gonadotropin concentrations in the testicular vein and in peripheral venous blood in seminoma patients. An analysis of various parameters. *Eur Urol* 1997;31:408–13 (EBM IIA).
- [22] Nichols CR. Testicular cancer. *Curr Probl Cancer* 1998;22:187–274.
- [23] Ondrus D, Hornak M, Breza J, et al. Delayed orchiectomy after chemotherapy in patients with advanced testicular cancer. *Int Urol Nephrol* 2001;32:665–7 (EBM IIB).
- [24] Simmonds PD, Mead GM, Lee AHS, et al. Orchiectomy after chemotherapy in patients with metastatic testicular cancer. *Cancer* 1995;75:1018–24 (EBM IIB).
- [25] Leibovitch I, Little JS, Foster RS, et al. Delayed orchiectomy after chemotherapy for metastatic nonseminomatous germ cell tumors. *J Urol* 1996;155:952–4 (EBM IIB).
- [26] Capelouto CC, Clark PE, Ransil BJ, et al. A review of scrotal violation in testicular cancer: is adjuvant local therapy necessary? *J Urol* 1995;153:981–5 (EBM IIA).
- [27] Harding M, Paul J, Kaye SB. Does delayed diagnosis or scrotal incision affect outcome for men with nonseminomatous germ cell tumors? *Br J Urol* 1995;76:491–4 (EBM IIB).
- [28] Leibovitch I, Baniel J, Foster RS, et al. The clinical implications of procedural deviations during orchiectomy for nonseminomatous testis cancer. *J Urol* 1995;154:935–9 (EBM IIB).
- [29] Robertson GS. Radical orchiectomy and benign testicular conditions. *Br J Surg* 1995;82:342–5 (EBM IIB).
- [30] Elert A, Olbert P, Hegele A, et al. Accuracy of frozen section examination of testicular tumors of uncertain origin. *Eur Urol* 2002;41:290–3 (EBM IIB).
- [31] Leroy X, Rigot J-M, Aubert S, et al. Value of frozen section examination for the management of nonpalpable incidental testicular tumors. *Eur Urol* 2003;44:458–60 (EBM III).
- [32] Steiner H, Hörtl L, Maneschg C, et al. Frozen section analysis-guided organ-sparing approach in testicular tumors: technique, feasibility, and long-term results. *Urology* 2003;62:508–13 (EBM III).
- [33] Weissbach L. Organ preserving surgery of malignant germ cell tumors. *J Urol* 1995;153:90–3 (EBM IIB).
- [34] Heidenreich A, Weissbach L, Hörtl W, et al., German Testicular Cancer Study Group. Organ sparing surgery for malignant germ cell tumor of the testis. *J Urol* 2001;166:2161–5 (EBM IIB).
- [35] Dieckmann KP, Loy V. Prevalence of contralateral testicular intraepithelial neoplasia in patients with testicular germ cell neoplasms. *J Clin Oncol* 1996;14:3126–32 (EBM IIA + IIB).
- [36] Hoei-Hansen CE, Rajpert-De Meyts E, Daugaard G, Skakkebaek NE. Carcinoma in situ testis, the progenitor of testicular germ cell tumors: a clinical review. *Ann Oncol* 2005;16:863–8 (EBM IIB).
- [37] Dieckmann K-P, Kulejewski M, Pichlmeier U, Loy V. Diagnosis of contralateral testicular intraepithelial neoplasia (TIN) in patients with testicular germ cell cancer: systematic two-site biopsies are more sensitive than a single random biopsy. *Eur Urol* 2007;51:175–85 (EBM IIB).
- [38] Kliesch S, Thomaidis T, Schütte B, et al. Update on the diagnostic safety for detection of testicular intraepithelial neoplasia (TIN). *APMIS* 2003;111:70–4 (EBM IIB).
- [39] Harland SJ, Cook PA, Fossa SD, et al. Intratubular germ cell neoplasia of the contralateral testis in testicular cancer: defining a high risk group. *J Urol* 1998;160:1353–7 (EBM IIA).
- [40] Giwercman A, Cantell L, Marks A. Placental-alkaline phosphatase as a marker of carcinoma-in-situ of the testis. Comparison with monoclonal antibodies M2A and 43-9F. *APMIS* 1991;99:586–94 (EBM IIB).
- [41] Giwercman A, Andrews PW, Jorgensen P, et al. Immunohistochemical expression of embryonal marker TRA-1-60 in carcinoma in situ and germ cell tumors of the testis. *Cancer* 1993;72:1308–14 (EBM IIB).
- [42] Daugaard G, Rørth M, von der Maase H, Skakkebaek NE. Management of extragonadal germ cell tumors and the

- significance of bilateral testicular biopsies. *Ann Oncol* 1992;3:283–9 (EBM III).
- [43] Fossa SD, Aass N, Heilo A, et al. Testicular carcinoma in situ in patients with extragonadal germ-cell tumours: the clinical role of pre-treatment biopsy. *Ann Oncol* 2003;14:1412–8 (EBM III).
- [44] Heidenreich A, Vorreuther R, Neubauer S, et al. Paternity in patients with bilateral testicular germ cell tumors. *Eur Urol* 1997;31:246–8 (EBM III).
- [45] Dieckmann KP, Besserer A, Loy V. Low-dose radiation therapy for testicular intraepithelial neoplasia. *J Cancer Res Clin Oncol* 1993;119:355–9 (EBM III).
- [46] Dieckmann KP, Loy V. The value of the biopsy of the contralateral testis in patients with testicular germ cell cancer: the recent German experience. *APMIS* 1998;106:13–20 (EBM IIB + III).
- [47] Petersen PM, Giwercman A, Skakkebaek NE, Rorth M. Gonadal function in men with testicular cancer. *Semin Oncol* 1998;25:224–33 (EBM III).
- [48] Christensen TB, Daugaard G, Geertsen PF, et al. Effect of chemotherapy on carcinoma in situ of the testis. *Ann Oncol* 1998;9:657–60 (EBM IIB).
- [49] Petersen PM, Giwercman A, Daugaard G, et al. Effect of graded testicular doses of radiotherapy in patients treated for carcinoma-in-situ in the testis. *J Clin Oncol* 2002;20:1537–43 (EBM IIB).
- [50] Classen J, Dieckmann KP, Bamberg M, et al. Radiotherapy with 16 Gy may fail to eradicate testicular intraepithelial neoplasia (TIN): preliminary communication of a dose-reduction trial of the German Testicular Cancer Study Group. *Br J Cancer* 2003;88:828–31 (EBM IIB).
- [51] von Ostau C, Krega S, Hartmann M, Rübber H. Metachronous contralateral germ cell tumor 7 years after management of testicular intraepithelial neoplasia by chemotherapy and multiple control biopsies. *Scand J Urol Nephrol* 2001;35:430–1 (EBM III).
- [52] Eble JN, Sauter G, Epstein JI, Sesterhenn IA. WHO classification of tumours. Pathology and genetics. Tumours of the urinary system and male genital organs. Lyon, France: IARC Press; 2004.
- [53] Sobin LH, Wittekind CH, editors. UICC: TNM classification of malignant tumours. ed. 6. New York: Wiley-Liss; 2002.
- [54] Fritz A, Percy C, Jack A, et al., editors. International classification of diseases for oncology (ICD-0). ed. 3. Geneva, Switzerland: World Health Organization; 2000.
- [55] Winstanley AM, Mikuz G, Debruyne F, et al. Handling and reporting of biopsy and surgical specimens of testicular cancer. *Eur Urol* 2004;45:564–73.
- [56] International Germ Cell Cancer Collaborative Group (IGCCCG). The International Germ Cell Consensus Classification: a prognostic factor based staging system for metastatic germ cell cancer. *J Clin Oncol* 1997;15:594–603.
- [57] Warde P, Specht L, Horwich A, et al. Prognostic factors for relapse in stage I seminoma managed by surveillance: a pooled analysis. *J Clin Oncol* 2002;20:4448–52 (EBM IIB).
- [58] Warde P, Gospodarowicz MK, Banerjee D, et al. Prognostic factors for relapse in stage I testicular seminoma treated with surveillance. *J Urol* 1997;157:1705–10 (EBM IIA).
- [59] Weissbach L, Bussar-Maatz R, Löhns U, et al. Prognostic factors in seminomas with special respect to HCG: results of a prospective multicenter study. *Eur Urol* 1999;36:601–8 (EBM IIA + III).
- [60] Horwich A, Alsanjari N, A’Hearn R, et al. Surveillance following orchiectomy for stage I testicular seminoma. *Br J Cancer* 1992;65:775–8 (EBM III).
- [61] Albers P, Siener R, Kliesch S, et al. Risk factors for relapse in clinical stage I nonseminomatous testicular germ cell tumors: results of the German Testicular Cancer Study Group trial. *J Clin Oncol* 2003;21:1505–12 (EBM IB).
- [62] Pont J, Hörtl W, Kosak D, et al. Risk-adapted treatment choice in stage I nonseminomatous testicular germ cell cancer by regarding vascular invasion in the primary tumor: a prospective trial. *J Clin Oncol* 1990;8:16–9 (EBM IIA).
- [63] Klepp O, Dahl O, Flodgren P, et al. Risk-adapted treatment of clinical stage I non-seminoma testis cancer. *Eur J Cancer* 1997;33:1038–44 (EBM IIA).
- [64] Ondrus D, Matoska J, Belan V, et al. Prognostic factors in clinical stage I nonseminomatous germ cell testicular tumors: rationale for different risk-adapted treatment. *Eur Urol* 1998;33:562–6 (EBM IIA + IIB).
- [65] Böhlen D, Borner M, Sonntag RW, et al. Long term results following adjuvant chemotherapy in patients with clinical stage I testicular nonseminomatous malignant germ cell tumors with high risk factors. *J Urol* 1999;161:1148–52 (EBM IIA).
- [66] Madej G, Pawinski A. Risk-related adjuvant chemotherapy for stage I non-seminoma of the testis. *Clin Oncol* 1991;3:270–2 (EBM IIB).
- [67] Read G, Stenning SP, Cullen MH, et al. Medical Research Council prospective study of surveillance for stage I testicular teratoma. Medical Research Council Testicular Tumors Working Party. *J Clin Oncol* 1992;10:1762–8 (EBM IIB).
- [68] Albers P, Ulbright TM, Albers J, et al. Tumor proliferative activity is predictive of pathological stage in clinical stage A non-seminomatous testicular germ cell tumors. *J Urol* 1996;155:579–86 (EBM IIB).
- [69] Sogani PC, Perrotti M, Herr HW, et al. Clinical stage I testis cancer: long term outcome of patients on surveillance. *J Urol* 1998;159:855–8 (EBM IIB + III).
- [70] White PM, Howard GC, Best JJ, et al. The role of computed tomographic examination of the pelvis in the management of testicular germ cell tumours. *Clin Radiol* 1997;52:124–9 (EBM IIB).
- [71] Heidenreich A, Schenkman NS, Sesterhenn IA, et al. Immunohistochemical expression of Ki-67 to predict lymph node involvement in clinical stage I nonseminomatous germ cell tumors. *J Urol* 1997;158:620–5 (EBM IIB).
- [72] de Riese WT, Albers P, Walker EB, et al. Predictive parameters of biologic behavior of early stage nonseminomatous testicular germ cell tumors. *Cancer* 1994;74:1335–41 (EBM III).
- [73] Moul JW, McCarthy WF, Fernandez EB, et al. Percentage of embryonal carcinoma and vascular invasion predict

- pathologic stage in clinical stage I non-seminomatous testicular cancer. *Cancer Res* 1994;54:1–3 (EBM III).
- [74] Albers P, Bierhoff E, Neu D, et al. MIB-1 immunohistochemistry predicts patients at low risk of metastasis in clinical stage I nonseminomatous testicular germ cell tumors. *Cancer* 1997;79:1710–6 (EBM III).
- [75] Heidenreich A, Sesterhenn IA, Mostofi FK, et al. Prognostic factors that identify patients with clinical stage I nonseminomatous germ cell tumors at low risk and high risk for metastasis. *Cancer* 1998;83:1002–11 (EBM III).
- [76] Alexandre J, Fizazi K, Mahe C, et al. Stage I non-seminomatous germ-cell tumours of the testis: identification of a subgroup of patients with a very low risk of relapse. *Eur J Cancer* 2001;37:576–82 (EBM III).
- [77] Nicolai N, Pizzocaro GA. A surveillance study of clinical stage I nonseminomatous germ cell tumors of the testis: a 10-year follow up. *J Urol* 1995;154:1045–9 (EBM III).
- [78] Sweeney CJ, Hermans BP, Heilman DK, et al. Results and outcome of retroperitoneal lymph node dissection for clinical stage I embryonal carcinoma-predominant testis cancer. *J Clin Oncol* 2000;18:358–62 (EBM III).
- [79] Sesterhenn IA, Weiss RB, Mostofi FK, et al. Prognosis and other clinical correlates of pathologic review in stage I and II testicular carcinoma: a report from the Testicular Cancer Intergroup Study. *J Clin Oncol* 1992;10:69–78 (EBM III).
- [80] Lijmer JG, Mol BW, Heisterkamp S, et al. Empirical evidence of design-related bias in studies of diagnostic tests. *JAMA* 1999;282:1061–6.
- [81] Gospodarowicz MK, Sturgeon JFG, Jewett MAS. Early stage and advanced seminoma: role of radiation therapy, surgery, and chemotherapy. *Semin Oncol* 1998;25:160–73.
- [82] Lashley D, Lowe B. A rational approach to managing stage I nonseminomatous germ cell cancer. *Urol Clin North Am* 1998;25:405–23.
- [83] Leibovitch I, Foster RS, Kopecky KK, et al. Identification of clinical stage A nonseminomatous testis cancer patients at extremely low risk for metastatic disease: a combined approach using quantitative immunohistochemical, histopathologic, and radiologic assessment. *J Clin Oncol* 1998;16:261–8.
- [84] Krug B, Heidenreich A, Dietlein M, et al. Lymphknotenstaging maligner testikulärer Keimzelltumoren. *Fortschr Röntgenstr* 1999;171:87–94.
- [85] White PM, Adamson DJA, Howard GCW, et al. Imaging of the thorax in the management of germ cell testicular tumours. *Clin Radiol* 1999;54:207–11 (EBM IIB + III).
- [86] Meyer CA, Conces DJ. Imaging of intrathoracic metastases of nonseminomatous germ cell tumors. *Chest Surg Clin N Am* 2002;12:717–38.
- [87] Barentsz J, Takahashi S, Oyen W, et al. Commonly used imaging techniques for diagnosis and staging. *J Clin Oncol* 2006;24:3234–44.
- [88] See WA, Hoxie L. Chest staging in testis cancer patients: imaging modality selection based upon risk assessment as determined by abdominal computerized tomography scan results. *J Urol* 1993;150:874–8.
- [89] McLeod DG, Weiss RB, Stablein DM, et al. Staging relationships and outcome in early stage testicular cancer: a report from the Testicular Cancer Intergroup Study. *J Urol* 1991;145:1178–83.
- [90] Leibovitch I, Foster RS, Kopecky KK, et al. Improved accuracy of computerized tomography based clinical staging in low stage nonseminomatous germ cell tumor using size criteria of retroperitoneal lymph nodes. *J Urol* 1995;154:1759–63.
- [91] Hogeboom WR, Hoekstra HJ, Mooyart EL, et al. Magnetic resonance imaging of retroperitoneal lymph node metastases of non-seminomatous germ cell tumors of the testis. *Eur J Surg Oncol* 1993;19:429–37.
- [92] Bellin M, Roy C, Kinkel K, et al. Lymph node metastases: safety and effectiveness of MR imaging with ultrasmall superparamagnetic iron oxide particles: initial clinical experience. *Radiology* 1998;207:799–808.
- [93] de Wit M, Hartmann M, Kotzerke J, et al., German Multi-center PET Study Group. 18F-FDG-PET in clinical stage I and II non-seminomatous germ cell tumors: first results of the German multicenter trial. *J Clin Oncol* 2005;23(Suppl):4504 (EBM IIB).
- [94] Huddart R, et al. A prospective study of 18 FDG PET in the prediction of relapse in patients with high risk clinical stage I (CSI) non-seminomatous germ cell cancer (NSGCT): MRC study TE22. *J Clin Oncol* 2006;24(Suppl):4520 (EBM IIB).
- [95] Hoh CK, Seltzer MA, Franklin J, et al. Positron emissions tomography in urological oncology. *J Urol* 1998;159:347–56.
- [96] Cremerius U, Wildberger JE, Borchers H, et al. Does positron emission tomography using 18-fluoro-2-deoxyglucose improve clinical staging of testicular cancer? Results of a study of 50 patients. *Urology* 1999;54:900–4.
- [97] Albers P, Bender H, Yilmaz H, et al. Positron emission tomography in the clinical staging of patients with stage I and II germ cell tumors. *Urology* 1999;53:808–11.
- [98] Weber WA, Avril N, Schwaiger M. Relevance of positron emission tomography (PET) in oncology. *Strahlenther Onkol* 1999;175:356–76.
- [99] Tsatalpas P, Beuthien-Baumann B, Kropp J, et al. Diagnostic value of 18F-FDG positron emission tomography for detection and treatment control of malignant germ cell tumors. *Urol Int* 2002;68:157–63.
- [100] Spermon JR, De Geus-Oei LF, Kiemeny LA, et al. The role of 18-fluoro-2-deoxyglucose positron emission tomography in initial staging and re-staging after chemotherapy for testicular germ cell tumours. *BJU Int* 2002;89:549–56.
- [101] Lassen U, Daugaard G, Eigtved A, et al. Wholebody positron emission tomography (PET) with FDG in patients with stage I non-seminomatous germ cell tumours (NSGCT). *Eur J Nucl Med Imaging* 2003;30:396–402.
- [102] Bokemeyer C, Nowak P, Haupt A, et al. Treatment of brain metastases in patients with testicular cancer. *J Clin Oncol* 1997;15:1449–54 (EBM III).
- [103] Fossa SD, Bokemeyer C, Gerl A, et al. Treatment outcome of patients with brain metastases from malignant germ cell tumors. *Cancer* 1999;85:988–97 (EBM III).
- [104] DeSantis M, Albrecht W, Höltl W, Pont J. Impact of cytotoxic treatment on long-term fertility in patients with germ-cell cancer. *Int J Cancer* 1999;83:864–5 (EBM III).

- [105] Jacobsen KD, Fossa SD, Bjoro TP, et al. Gonadal function and fertility in patients with bilateral testicular germ cell malignancy. *Eur Urol* 2002;42:229–38 (EBM III).
- [106] Fossa SD, Dahl AA, Haaland CF. Health-related quality of life in patients treated for testicular cancer. *Curr Opin Urol* 1999;9:425–9.
- [107] Kliesch S, Behre HM, Jürgens H, et al. Cryopreservation of semen from adolescent patients with malignancies. *Med Pediatr Oncol* 1996;26:20–7.
- [108] Kliesch S, Kamischke A, Nieschlag E. Cryopreservation of sperm. In: Nieschlag E, Behre HM, editors. *Andrology—male reproductive health and dysfunction*. Berlin-Heidelberg-New York: Springer; 1997. p. 349–58.
- [109] Dieckmann KP, Loy V. Paternity in a patient with testicular seminoma and contralateral testicular intraepithelial neoplasia. *Int J Androl* 1993;16:143–6 (EBM IV).
- [110] Giwercman A, von der Maase H, Rorth M, et al. Semen quality in testicular tumour and CIS in the contralateral testis. *Lancet* 1993;341:384–5 (EBM III + IV).
- [111] Giwercman A, von der Maase H, Rorth M, et al. Current concepts of radiation treatment of carcinoma in situ of the testis. *World J Urol* 1994;12:125–30 (EBM III + IV).
- [112] Kliesch S, Bergmann M, Hertle L, et al. Semen parameters and testicular pathology in men with testicular cancer and contralateral carcinoma in situ or bilateral testicular malignancies. *Hum Reprod* 1997;12:2830–5 (EBM III + IV).
- [113] Nieschlag E, Behre HM. Pharmacology and clinical use of testosterone. In: Nieschlag E, Behre HM, editors. *Testosterone: action, deficiency, substitution*. Berlin-Heidelberg-New York: Springer; 1999. p. 92–114.
- [114] Dodds L, Marrett LD, Tomkins DJ, et al. Case-control study of congenital anomalies in children of cancer patients. *Br Med J* 1993;307:164–8 (EBM III).
- [115] Warde PR, Gospodarowicz MK, Goodman PJ, et al. Results of a policy of surveillance in stage I testicular seminoma. *Int J Radiat Oncol Biol Phys* 1993;27:11–5 (EBM IIB).
- [116] Warde P, Gospodarowicz MK, Panzarella T, et al. Stage I testicular seminoma: results of adjuvant irradiation and surveillance. *J Clin Oncol* 1995;13:2255–62 (EBM IIB).
- [117] Oliver RT, Mason MD, Mead GM, et al. Radiotherapy versus single-dose carboplatin in adjuvant treatment of stage I seminoma: a randomized trial. *Lancet* 2005;366:293–300 (EBM IB).
- [118] Dieckmann KP, Brüggeboes B, Pichlmeier U, et al. Adjuvant treatment of clinical stage I seminoma: is one single course of carboplatin sufficient? *Urology* 2000;55:102–6 (EBM IIB).
- [119] Mason M, Jones W. Treatment of stage I seminoma: more choice, more dilemmas. *Clin Oncol* 1997;9:210–2 (EBM IIB).
- [120] Krega S, Kalund G, Otto T, et al. Phase II study: adjuvant single agent carboplatin therapy for clinical stage I seminoma. *Eur Urol* 1997;31:405–7 (EBM IIB).
- [121] Aparacio J, Germa JR, Garcia del Muro X, et al. Risk-adapted management for patients with clinical stage I seminoma: the Second Spanish Germ Cell Cancer Cooperative Group study. *J Clin Oncol* 2005;23:8717–23, (EBM IIB).
- [122] Sternberg CN. The management of stage I testis cancer. *Urol Clin North Am* 1998;25:435–49 (EBM IIB).
- [123] von der Maase H, Specht L, et al. Surveillance following orchietomy for stage I seminoma of the testis. *Eur J Cancer* 1993;29A:1931–4 (EBM IIB).
- [124] Dieckmann KP, Albers P, Classen J, et al. Late relapse of testicular germ cell neoplasms. A descriptive analysis of 122 cases. *J Urol* 2005;173:824–9 (EBM IIB).
- [125] Baniel J, Foster RS, Gonin R, et al. Late relapse of testicular cancer. *J Clin Oncol* 1995;13:1170–6 (EBM III).
- [126] Fossa SD, Moynihan C, Serbuti S. Patients' and doctors' perception of long-term morbidity in patients with testicular cancer clinical stage I. *Support Care Cancer* 1996;4:118–28 (EBM III).
- [127] Fossa SD, Horwich A, Russel JM. Optimal planning target volume for stage I testicular seminoma: a Medical Research Council randomized trial. *J Clin Oncol* 1999;17:1146–54 (EBM IB).
- [128] Jones WG, Fossa SD, Mead GM, et al. Randomized trial of 30 versus 20 Gy in the adjuvant treatment of stage I testicular seminoma: a report on Medical Research Council Trial TE 18, European Organisation for the Research and Treatment of Cancer Trial 30942. *J Clin Oncol* 2005;23:1200–8 (EBM IB).
- [129] Kiricuta IO, Sauer J, Bohndorf W. Omission of the pelvic irradiation in stage I testicular seminoma: a study of postorchietomy paraaortic radiotherapy. *Int J Radiat Oncol Biol Phys* 1996;35:293–8 (EBM IIA).
- [130] Bamberg M, Schmidberger H, Meisner C, et al. Radiotherapy for stage I. IIA/B testicular seminoma. *Int J Cancer* 1999;83:823–7 (EBM IIA).
- [131] Power RE, Kennedy J, Crown J, et al. Pelvic recurrence in stage I seminoma: a new phenomenon that questions modern protocols for radiotherapy and follow-up. *Int J Urol* 2005;12:378–82 (EBM III).
- [132] Taylor MB, Carrington BM, Livsey JE, Logue JP. The effects of radiotherapy treatment changes on sites of relapse in stage I testicular seminoma. *Clin Radiol* 2001;56:116–9 (EBM III).
- [133] Joos H, Sedlmayer F, Gomahr A, et al. Endocrine profiles after radiotherapy in stage I seminoma: impact of two different radiation treatment modalities. *Radiation Oncol* 1996;43:159–62 (EBM IIB).
- [134] Stahl O, Eberhard J, Jepson K, et al. Sperm DNA integrity in testicular cancer patients. *Hum Reprod* 2006;21: 3199–205 (EBM IIA).
- [135] Dosman MA, Zagars GK. Postorchietomy radiotherapy for stages I and II testicular seminoma. *J Radiat Oncol Biol Phys* 1993;26:381–90 (EBM IIB).
- [136] Zagars GK. Management of stage I seminoma: radiotherapy. In: Horwich A, editor. *Testicular cancer: investigation and management*. London, UK: Chapman & Hall; 1996. p. 99–106 (EBM IIB).
- [137] Bokemeyer C, Schmoll HJ. Secondary neoplasms following treatment of malignant germ cell tumors. *J Clin Oncol* 1993;11:1703–9 (EBM III).
- [138] Travis LB, Curtis RE, Storm H, et al. Risk of second malignant neoplasms among long-term survivors of testicular cancer. *J Natl Cancer Inst* 1997;89:1429–39 (EBM III).

- [139] Travis L, Andersson M, Holowaty E, et al. Risk of leukemia following radiotherapy and chemotherapy for testicular cancer. *Proc Am Soc Clin Oncol* 1999;18:308a (abstract no. 1185) (EBM III).
- [140] Spermon JR, Roeleveld TA, van der Poel HG, et al. Comparison of surveillance and retroperitoneal lymph node dissection in stage I nonseminomatous germ cell tumors. *Urology* 2002;59:923–9 (EBM IIB, EBM IIA).
- [141] Oliver RT, Ong J, Shamash J, et al. Long-term follow-up of Anglian Germ Cell Cancer Group surveillance versus patients with Stage I nonseminoma treated with adjuvant chemotherapy. *Urology* 2004;63:556–61 (EBM IB).
- [142] Donohue JP, Thornhill JA, Foster RS, et al. Retroperitoneal lymphadenectomy for clinical stage A testis cancer (1965–1989): modifications of technique and impact on ejaculation. *J Urol* 1993;149:237–43 (EBM III).
- [143] Maroto P, Garcia del Muro X, et al. Multicentre risk-adapted management for stage I non-seminomatous germ cell tumours. *Ann Oncol* 2005;16:1915–20 (EBM IIB).
- [144] Rustin GJ, Mead GM, Sally P, et al. Randomized trial of two or five computed tomography scans in the surveillance of patients with stage I nonseminomatous germ cell tumors of the testis: Medical Research Council Trial TE08. ISRCTN56475197 – The National Cancer Research Institute Testis Cancer Clinical Studies Group. *J Clin Oncol* 2007;10:1310–5 (EBM IB).
- [145] Nicolai N, Miceli R, Artusi R, et al. A simple model for predicting nodal metastases in patients with clinical stage I nonseminomatous germ cell testicular tumors undergoing retroperitoneal lymph node dissection only. *J Urol* 2004;171:172–6 (EBM III).
- [146] Albers P, Siener R, Kregel S, et al. One course of adjuvant PEB chemotherapy versus retroperitoneal lymph node dissection in patients with stage I non-seminomatous germ-cell tumors (NSGCT): results of the German Prospective Multicenter Trial (Association of Urological Oncology [AUO]/German Testicular Cancer. *J Clin Oncol* 2006 ASCO Annual Meeting Proceedings Part I. Vol 24, No. 18S (June 20 suppl) 2006:4512 (EBM IB).
- [147] Chevreau C, Mazerolles C, Soulié M, et al. Long-term efficacy of two cycles of BEP regimen in high-risk stage I nonseminomatous testicular germ cell tumors with embryonal carcinoma and/or vascular invasion *Eur Urol* 2004;46:209–15 (EBM IIB).
- [148] Fossa SD, Aass N, Winderen M, et al. Long-term renal function after treatment for malignant germ-cell tumours. *Ann Oncol* 2002;13:187–9 (EBM IB).
- [149] Pont J, Albrecht W, Postner G, et al. Adjuvant chemotherapy for high-risk clinical stage I nonseminomatous testicular germ cell cancer: long-term results of a prospective trial. *J Clin Oncol* 1996;14:441–8 (EBM IIA).
- [150] Cullen MH, Stenning SP, Parkinson MC, et al. Short-course adjuvant chemotherapy in high-risk stage I non-seminomatous germ cell tumors of the testis: a Medical Research Council report. *J Clin Oncol* 1996;14:1106–13 (EBM III).
- [151] Meinardi MT, Gietema JA, van der Graaf WT, et al. Cardiovascular morbidity in long-term survivors of metastatic testicular cancer. *J Clin Oncol* 2000;18:1725–32 (EBM III).
- [152] Strumberg D, Brugge S, Korn MW, et al. Evaluation of long-term toxicity in patients after cisplatin-based chemotherapy for non-seminomatous testicular cancer. *Ann Oncol* 2002;13:229–36 (EBM III).
- [153] Huddart RA, Norman A, Shahidi M, et al. Cardiovascular disease as a long-term complication of treatment for testicular cancer. *J Clin Oncol* 2003;21:1513–23 (EBM III).
- [154] Sagstuen H, Aass N, Fossa SD, et al. Blood pressure and body mass index in long-term survivors of testicular cancer. *J Clin Oncol* 2005;23:4980–90 (EBM III).
- [155] Nuver J, Smit AJ, van der Meer J, et al. Acute chemotherapy-induced cardiovascular changes in patients with testicular cancer. *J Clin Oncol* 2005;23:9130–7 (EBM III).
- [156] Hartmann JT, Albrecht C, Schmoll HJ, et al. Long term effects on sexual function and fertility after treatment of testicular cancer. *Br J Cancer* 1999;80:801–7 (EBM III).
- [157] Bohlen D, Burkhard FC, Mills R, et al. Fertility and sexual function following orchiectomy and two cycles of chemotherapy for stage I high risk nonseminomatous germ cell cancer. *J Urol* 2001;165:441–4 (EBM III).
- [158] Brydoy M, Fossa SD, Klepp O, et al. Paternity following treatment for testicular cancer. *J Natl Cancer Inst* 2005;97:1580–8 (EBM III).
- [159] Travis LB, Fossa SD, Schonfeld SJ, et al. Second cancers among 40,576 testicular cancer patients: focus on long-term survivors. *J Natl Cancer Inst* 2005;97:1354–65 (EBM III).
- [160] Weissbach L, Boedefeld EA, Horstmann-Dubral B. Surgical treatment of stage-I non-seminomatous germ cell testis tumor. Testicular Tumor Study Group Bonn. *Eur Urol* 1990;17:97–106 (EBM IIA).
- [161] Donohue JP, Foster RS, Rowland RG, et al. Nervesparing retroperitoneal lymphadenectomy with preservation of ejaculation. *J Urol* 1990;144:287–92 (EBM III).
- [162] Donohue JP, Thornhill JA, Foster RS, et al. The role of retroperitoneal lymphadenectomy in clinical stage B testis cancer: the Indiana University experience (1965 to 1989). *J Urol* 1995;153:85–9 (EBM III).
- [163] Baniel J, Foster RS, Rowland RG, et al. Complications of primary retroperitoneal lymph node dissection. *J Urol* 1994;152:424–7 (EBM III).
- [164] Heidenreich A, Albers P, Hartmann M, et al. Complications of primary nerve-sparing retroperitoneal lymph node dissection on clinical stage I nonseminomatous germ cell tumors of the testis. German Testicular Cancer Study Group. *J Urol* 2003;169:1710–4 (EBM III).